Post-Mortem Book

of

the Montreal General Hospital

for the year ending

May 1st 1877

Pathologist

Dr Osler

General Index

Case

I Hypertrophic Cirrhosis
II Typhoid Fever – Perforation
III Pneumonia
IV Caries vertebrarum. Phthisis. Amyloid deg.
V Syphiloma of Liver
VI (Still-born Infant.)
VII Tubercular Peritonitis
VIII Myelitis
IX
X Pneumonia – Meningitis
XI Phthisis
XII Pulmonary Gangrene
XIII Morbus Brightii. &c.
XIV Cerebritis?
XV Pneumonia Croupous Colitis
XVI Aortic Valve Disease
XVII Tuberculosis – sp. Meninges affected)
XVIII Phthisis
XIX Cholera? Canadian.
XX Peritonitis. Pelvic Abscess
XXI Tuberculous Nephritis & Vesicitis
XXII Calculus Vesicæ. Lithotomy
XXIII Typhoid Fever. 2
XXIV Cancer of Stomach.
XXV Perinephritic Abscess. Pyæmia
XXVI Typhoid. Fever. 3

9363
~~13831~~

Case		
XXVII	Phthisis	
XXVIII	Typhoid Fever. Perforation	4
XXIX	Puerperal Pyaemia	
XXX	Thickening of Stomach and Colon	
XXXI	Variola Haemorrhagica	
XXXII	Perforating Ulcer of Caecum	
XXXIII	Typhoid Fever	5
XXXIV	Typhoid Fever	6
XXXV	Pneumonia	
XXXVI	Aortic Aneurism. Erosion of dorsal vertebrae. Acute Tuberculosis	
XXXVII	Calculus Vesicae	
XXXVIII	Febroid Phthisis	
XXXIX	Heart Disease from Over work	
XL	Phthisis	
XLI	Epithelioma cervix uteri	
XLII	Morbus Brightii	
XLIII	Tubercular Meningitis	
XLIV	Pleurisy. Pul. Apoplexy. Morbus Cord.	
XLV	Cancer of Tongue & Pyaemia	
XLVI	—	
XLVII	Albuminuria. Pregnancy. Peritonitis	
XLVIII	Phthisis. Haemoptysis	
XLIX	Aortic Aneurism. Rupture into R. pleura	
L	Aortic Valve Disease	
LI	Pleuro-Pneumonia	
LII	Cancer of Tongue and Liver	
LIII	Aneurism of Hepatic Aneurism. Sup. Hepatic	

Case	
LIV	Tuberculous Nephritis & Pyelitis
LV	Primary Cancer of Liver
LVI	Phthisis
LVII	Emphysema
LVIII	Pyelitis
LIX	Ovarian Tumor. Operation. Peritonitis
LX	Pneumonia
LXI	Progressive Pernicious Anaemia
LXII	Diabetes. Lobar Pneumonia
LXIII	Phthisis, Acute Pleura-Pneumonia
LXIV	Abscess of Brain
LXV	Typhus Fever
LXVI	Bright's Disease
LXVII	Pleurisy. Fibroid degeneration of Heart
LXVIII	Phthisis
LXIX	Typhus Fever
LXX	Diphtheria
LXXI	Fracture 1st & 2nd Ribs Emphysema
LXXII	Ovarian Tumour
LXXIII	Cancer of Stomach Perforation
LXXIV	Pleuritis dextra Pneumonia sinistra
LXXV	General Tuberculosis
LXXVI	Tubercular Meningitis
LXXVII	Pericarditis acut.
LXXVIII	Cirrhosis of Liver
LXXIX	Tuberculous Nephritis
LXXX	Phthisis

Case	
LXXXI	Phthisis. Pneumo-thorax. Dermoid Cyst.
LXXXII	Phthisis. Primary Cancer of Vertebra
LXXXIII	Necrosis Tibiæ. Pyæmia
LXXXIV	Cancer of Gall-bladder
LXXXV	Ovarian Tumour. Peritonitis
LXXXVI	Pneumonia
LXXXVII	Pneumonia. Aortic Aneurism (Sent elsewhere)
LXXXVIII	~~Lod~~ Pylephlebitis
LXXXIX	Traumatic Apoplexy
XC	Pneumonia
XCI	Kyphosis. Bronchitis. Pulmonary Collapse
XCII	Ileus
XCIII	Typhoid Fever - Perforation
XCIV	Calculus vesicæ
XCV	Pneumonia
XCVI	Acute Necrosis of Femur. Pyæmia
XCVII	Leukæmia.
XCVIII	Pneumonia
XCIX	Convulsions
C	Epilepsy

Special Index

General Index

Case	
I	Cirrhosis of the Liver - with enlargement
II	Typhoid Fever - perforation (1)
III	Pneumonia (1) ✓
IV	Caries Vertebræ. Phthisis. Amyloid disease
V	Syphiloma of Liver
VI	Still-born Infant
VII	Tubercular(?) Peritonitis.
VIII	Grey degeneration. Spinal Cord
IX	
X	Pneumonia - Meningitis (2) ✓
XI	Phthisis (1)
XII	Pulmonary Gangrene
XIII	Morbus Brightii - acute
XIV	Cerebritis(?)
XV	Pneumonia. Croupous Colitis (3)
XVI	Aortic valve Disease
XVII	Tuberculosis - general. Spinal Meninges.
XVIII	Phthisis (2)
XIX	Cholera? Canad.
XX	Peritonitis - Pelvic abscess
XXI	Tuberculous Nephritis & Vesicitis
XXII	Calculus Vesic. Lithotomy
XXIII	Typhoid Fever 2
XXIV	Cancer of Stomach
XXV	Perinephritic abscess. Pyæmia
XXVI	Typhoid Fever 3
XXVII	Phthisis (3)

General Index

rifice obliter 275, perforation of 275.

Aortic valves. Calcareous masses 123. 214
teries atheromatous 128
Innominate, dilated at origin 156
Hep. aneur. of 170
scaris lumbricoides, 78. 147. 223.

ronchi. pus in, 124, Blood clots in bronchioles 150 Inflam & ecchym 287,
ronchial Glands Caseous 127, 136, 234 Enlarged 153, 185. 263, 267, 284
Brain abscess of 206
ong. sinus. clot in 122, 184
rteries atheromatous 165. 189, 307

ubercles granular 134, 154.

Special Index

p con. c inf Por vein, 375.

ceum. 330,

pith. Skin of trunk 237
ocardium
Fat thickening 232

Epiglottis. ulcers of 318

mpyaema 324, 371 pus in compartments,

ramen Ovale. valvular closure 286, . not quite closed 408,

ractures. 1st & 2nd rib 324

Cancer of 359. clot in. 359
all Stones. 3. 225, 359 . Walls infiltrated with cancer 323, . Enorm. distend 358

Coron arter. 134 258. form 264. atheroma 394
Coronary vein. large. to valve present 257.
Heart Displaced. 219, 257, Musculi papillaris, fibroid 221, 223, 238, 311

Dilated. right aur & vent. 221, 286, 321, 386, left vent 238 257, rt. aur. 257. R.V. 257

Fatty 238, 259, 298. 409 . Eustach valve persists 257. . Abscess 356

um. P.M. invagination 242 Fibroid deg. of muscle 314

ntestines. Shrunken 333. . Amyloid & m. 340; 375. Knotted of old band 394

Hernia omental in scrotum 409

318, 381, 311 (infants)
Kidney. Surface granular. 222 224, 259, 264, 311 Puckerings 239
" Cortex diminished 222, 224, 227, 230. 311
" Arteries prominent. 224, 230, 264, 311. Lobular (still) 261. Papillae eroded 395
" Organ firm. 224, 329. Tubercul. cystic. 272, 291, 371. Parts infiltr. with blood 408
an large. 272. , Pelvis. dilated large. 262, 395. Organ lobulated 348.
" Calculi in 395
Liver. Grooves, 228 Local atrophy above G. bladder 230, 368
" Slightly granular. 244, 368. Greatly displaced 347. Sup. of V. Portae. 376
" Cancer. 264, 279, 352, 359. Much enlarged 10½ lbs. 268. Atrophy of left lobe 395.
Calcareous nodule, 407

Lungs. Adherent. slightly. 224, 232, 263. 343. 347
Fibroid 220. Fib. bands 348, 410 Cretaceous nodules 309
Puckered. at apex 226, 229, 242, 243, 340, 362, 405. 410
Lobular Pneumonia 239 Right mid lobe infl. [illegible] 340, L. L. up lobe fissured 367
396
Oedema 246, 250, 261, 266, 276, 288, 363, 385. Perforation of 348

Mediastinum ant. pus in 241, lymph & gland infilt 362.
Meningitis simple Tubercul. 232

Orifices dilated. 257. stenosis of 380
389, 399. 405
Mitral valves atheromatous at bases. 223, 264, 275, 338, 366 Calcar. nodules 238
349
Ovaries. Corp. luteum 236. small ped. fibroid 346. Dermoid cyst. 349 Tumour of left. 36
" very cicatricial. 244, cystic 382
Oxyuris vermicularis, in caecum 323
Pelvis. Chron. [illegible] of 358.

Portal vein. clot in 28

Air in 360.

harynx. Tub. ulcer of. 345

leura. Effusion into 237. (96oz) (Blood in right. 3½ lbs.). 260. 303, 7pts 313, 316 331(3½ pts), 347, 371, 394

adhes. & pigmentation 309 . Fluid in Compartments of. 313. Osseous & cart. plate 395

Pneumo-thorax. p 347.

ulmonary veins. very large 229, coagula in 406

" " art - aneurism on branch. in cavity. dilated. 259, 288.

ibs. cart of. eroded 255

igmoid Flexure. long & crossing pelvis 235 S. Vein. thrombus in 398,

leen. small 60 grms 264. adher. to Sto. 267, 277

atin. 277 . Firm & dense 315; cicatrices 381

artilage plates in Capsule 229

um. P. Mesoplenum 236 Small ulcers. 278, 289 . White round spots Lent. glands (?) 339

Mammillated 302, 339. perforation of 328. Ecchymoses 407

chea. trns memb. ossified. 298

Ir[illegible] infer. slipt. narrowed 380

Trichinae Spiralis in muscles 408.

Glenus. clot in. 310

lenic vein Closed at end, thrombus 378

M.L. 1988
Ent'd to O.L 1988.

Cirrhosis with enlargement (11)

3

Case.-1.- James Hargreaves.- 34.-E.E.M.
3rd May.- 4th May.- 1876.-
General appearance of body.- Well nourished-
Medium muscular development -
Rigor Mortis present:- One or two
spots of purpura- One very evident
on anterior surface of left arm.-
On making preliminary incision on
panniculus adiposus will develop
Muscles normal looking.- On
cutting through skin of head
numerous ecchymoses.
On opening Thorax " nothing unusual
on superficial examination Lungs
moderately pigmented On opening
pericardium 3vi.- fluid present
in sac.- No Ecchymoses either
there- A layer of fat covers the
right ventricle concealing the
muscular substance entirely.-
Pleural Cavity.- No ecchymoses visible
Running along lower border of ribs
a layer of fat extending from
lower border towards inter costal
space beneath in some cases
projecting as a small fold.-

Cerrhosis liver
Oed. lungs
Chr. scler. mit. endo^{c}.
Cat. gastr^{is}

Apical scars

Lungs.- Slight Puckering at apices No nodules felt in either lung. Lungs Crepitant throughout. with exception of lower ~~lobe~~ part of lower lobe on left side which is in a state of collapse.- Small portion of collapse also seen in the upper lobe, anterior border in the portion which covers the heart. At base of left lung beneath pleura are five or six small extravasations one about size of a sixpence.- On cutting into the lung a large amount of frothy serum mixed with blood escaped.- Posterior portion of lungs congested.- Bronchial mucous membrane not congested. a small amount of yellow frothy serum

Compare Oldmead lungs.

Heart.- A considerable amount of fat, apparently externally especially over the right ventricle.- Right ventricle open. Tricuspid orifice. Valves healthy. Anterior segment thickened a little at free edge. Valves tinged yellow.- Pulmonary valves healthy No clots in right ventricle Mitral valve stained light yellow. Margins considerably thickened & thickening extends to Chordæ Tendineæ

Bases of aortic Semilunar firm and atheromatous: Atheroma extends on to posterior segment of the mitral. Valves healthy. Corpora Arantii well marked. Margin of one valve fenestrated. Liver enlarged with Cirrhosis. Weight of Heart 14½ oz. Weight of Pancreas 3¼ oz. Weight of Spleen 19 oz. Amt. of blood in Stomach 6 oz; mingled with clots and semi-gummous. Obstruction in Portal Circulation.

Catarrhal Gastritis

Stomach, mucous memb. dark livid red at dependant part — brighter at cardiac — thickened tears readily under nail — covered with bloody mucous — Scattered over are numerous small Ecchymotic spots. **Weight of Liver** lb. 6. ℥ 11¾

Left Alcoholic Cirrhosis Liver

Surface of Liver studded with small firm projections, size millet-seed to pea. Projecting nodules dark color, intervening tissue being white. Nodules are very evident at anterior free border and left lobe. On under surface of left lobe are several very large nodules. Portal Vein large — no clots. Gall-bladder elongated & filled with mass of inspissated bile. Towards orifice of bile-duct the inspiss bile is collected into 3 small balls:

Spleen wt 19 oz. Capsule little thickened slty puckered in places, on section pulp soft dark purplish red color very friable

Rt Kidney 9½ oz Capsule readily detached thin transparent

Surface kidney yellowish in color stars of Verheyen venae stellatae beautifully mottled. on section surface of a greenish yellow color, proportion of cortex to pyramids tolerably natural. close inspection of pyramids shows that the tubules in many places are filled with dark greenish material Left kid 8 oz on section rather more bld flowed fr this kidney than rt gen appearance same sizable amt of fat abt pelvis

Brain 3 lbs 1/2 oz. Calvarium mod thick inner surface deeply grooved by meningl. arteries diploe dark red color Dura mater normal appearance longitudinal sinus free fr clot pacchionian granulations numerous on under surface dura closely adherent on either side longitudinal fissure surface brain not membranes not thickened — brain on section looks healthy very little fld in ventricles puncta vasculosa moderately marked, bld wh leaves stains rendering pt of a yellowish color: Cerebellum med ob & pons healthy bladder contains 15 oz fluid — mesentery loaded c fat: intestines small very dark color externally. filled with qty of dark changed blood lumen mucosa stained no ecchymoses noticed — Keep liver. contents of gallbldr —

Pancreas wt 3 1/4 oz:

Typh. – Perf.
Hydrothorax.
Fenestr. g valvr.
Peritonr.
Ac swelg of spleen.

Typhoid Fever Perforating after 2 weeks convalescence 5

Case 2nd May 15th 76

Abram Philips aged 18.
Gen. appearance of body. Rigor Mortis
present in Moderate degree.
Body bloody Still nourished
Considerable amount of discoloration
on Posterior parts of the body.
Head. Considerable amt of blood on post.
parts of the scalp.
Calvarium Normal.

Brain

Dura mater normal. Dark fluid blood, and
one long thin clot in Long. Sinus.
Arachnoid opaque & cloudy in several places in
the lateral and superior regions.
Pia mater natural. The larger veins contained air
Brain substance healthy, a little soft in the centre
Ventricles. contained about 3ii of clear fluid

Thorax

3ifs. of bloody fluid in right 3iiifs in left pleural
sac.

Lungs. congested posteriorly. crepitant throughout
very little pigment.

Pericardium 3iii of clear fluid. No patches of attrition
Heart. Chambers and valves normal. Endocardium
deeply stained (post-mortem). One valve of aorta penetrated
Muscle substance pale.

Abdomen (moderately distended)

On opening this cavity the coils of small intestines which were uppermost presented a beautiful rose-red appearance - the first stage of peritonitis. no lymph on their surfaces pints of dark fluid mixed with faecal matter removed from the peritoneal cavity. Parietal peritoneum not affected. The intense hyperaemia of the visceral layer was confined to the surfaces of the coils which lay near the abd. walls, the deeper portions, even near the point of perforation were not congested. a few flakes of lymph were found on some parts of the ileum. On carefully examining the intestines a small perforation was found about 8 inches above the valvula Bauhinii, & through it faecal matter was oozing. On removing the ileum the perforation was found to be situated at the bottom of an ulcer about the size of a half dollar and looking like a button hole slit about 4 lines in length & 2 in breadth (○) It corresponded to the point opposite the attachment of the mesentery. The M. M. about it was not much inflamed. Yellowish faecal matter adhered to its edges Six to eight other ulcers were found in this portion of the bowel, most of them small, rounded rather than elongated and from their general appearance seemed to have made some progress towards healing. The solitary glands were also enlarged looking like small peas beneath the M. M. No ulceration in the caecum

Stomach. healthy

Spleen 3 19. dark red in colour. very friable

Liver 5 lbs. 10 oz. Pale. soft. somewhat enlarged. and

On section was bloodless and of dirty clay-colour

Kidneys

Weight 31½ g each. Capsule readily detached somewhat congested. Otherwise healthy

Lobar Pneumonia

Case 3rd

May. 16th 1876

M. Wilson aet. 28.

Body tolerably well nourished Rigor Mortis present in a slight degree especially in the legs. Lividity occupy about the neck & along some of the veins.

Lungs.

Right Lung. Middle lobe & anterior portion of upper lobe healthy. Lower lobe posteriorly in a state of engorgement. The whole the lower lobe with the exception of a small portion at the base in a condition of red hepatization presenting in section the usual appearance of that condition Many of the bronchial tubes are filled with fibrinous plugs. A puckered cicatrix exists at the apex of this Lung.

Left Lung. Very much congested posteriorly - otherwise healthy.

Heart

Right auricle filled with a large semisolid clot of a dark color Right Ventricle also contains clot. Left Ventricle. Muscle substance pale. Mitral valves slightly thickened at the edges. Aortic valves healthy. One segment of Aortic & one segment of Tricuspid valves fenestrated

Lob. pneum. R. L. lobe.

Liver. 60 Oz.

Tolerably firm on Section
Slight amount of Hepatic Congestion
Gall Bladder contains two gall Stones
Spleen 3 to 11

Five small Tumours
round in Margin Congested purplish red in color soft and friable

Kidneys.

Congested. Left Kidney 3 to 4 p
Right Kidney 3 to. Proportion between
Cortex & Medulla normal. Capsule
readily detached

Brain 1 lb 9 Oz.

Small clot in Longitudinal
Sinus. Dura Mater normal Arachnoid Healthy Vessels of Pia Mater large
and small deeply injected
Substance of Brain on Section Healthy
Ventricles & Septum Lucidum a little soft.

Stomach.

Mucous Membrane congested
Numerous Ecchymoses over the Surface
Chiefly Capillary
Intestines

Healthy No Ulcers of Ileum
in the Ileum thoroughout Solitary
and Typhoid two years ago although
said Ulcers had Typhoid now.

Larynx Intestine.

Lungs Healthy.

Bladder Healthy also

J. Mumford

This case of special interest as diagnosis of Typh fever had been made

Chr. tuberc. c̄ cav.
Fenest. valves
Colitis
Cyst of Fall. tube.
Amyloid disease.

Case 4th Phthisis. Caries of Vertebræ Amyloid degeneration

10

Mary Naughton Died 16th May 76

Body very much emaciated. Calvarium thick and heavy. Dura Mater healthy soft grumous clot in longitudinal Sinus Surface of brain pale and anæmic. Convolutions wasted. Sulci very wide.

Caries of the Vertebræ.

Lungs. Crepitant, on section numerous tubercles scattered through its substance. Chiefly collected in upper part. a dark fibrous Cicatrix exists at upper part. chiefly collected into groups of tubercles. A Small Cavity filled with bloody fluid exists behind.

Left Lung.

Similar Condition to former numerous tubercles in groups a considerable amount of dark hard fibrous tissue exist around the groups. No Cavities in this organ.

Heart. weight. 8oz. muscular fibre pale probably from fat Tricuspid & pulmonary valves healthy. Mitral valves a little thickened Aortic valves healthy and fenestrated slight amount of thickening at base of valves.

Liver weight 5 lbs. extending into left hypochondriac region touching the Spleen. Shape somewhat altered anterior border slightly anteverted extreme left border bent upon itself under surface presenting a deep fissure. on section pale bloodless firm to touch and presenting the usual glistening appearance of Amyloid degeneration. Application of Iodine followed by the usual reaction.

on carefully examining a section of surface it is seen that portions are of a brownish - of a darker red color than the others & it is these portions which stain with the Iodine

Spleen. 3rd.

In Section of a purplish red and on carefully examining a number of small glistening points are seen and it is these points which on the application of Iodine are stained R. when show the Amyloid reaction

The organ has not the usual firmness of an Amyloid organ.

Kidneys.

3rd each Capsule slightly thickened and somewhat adherent to the organ Surface somewhat puckered Section Kidneys pale. The vessels of the Pyramids alone contain blood. organ very firm to the touch but Hardly any traces of Amyloid degeneration in them

Stomach.

Mucous Membrane soft numerous ecchymoses & staining on the line of the vessels

Small Intestines

Amyloid reaction

Faintly marked in them Mucous Mem-

By Ulcerations Small intestine
Large Intestine.

An irregular perforation
Ulcer. Exists about 2 feet from the
Ileo Cæcal valve about the size of
a half dollar The edges are irregular
slightly raised & base formed by the
Muscular layer.

Small follicular Ulcers exist in the
Course of the Colon becoming much
more numerous as we approach the
rectum. In the portion of the bowel
they are very closely set together &
look like small holes punched
in the Mucous
Ulcers.

Healthy. A small cyst filled
with cheesy matter in one of the
Fallopian tubes
Ovaries.

Normal.

James Kell

Case 5th May 18th. Syphilis of Liver

Thomas Mann. aged 24. Entered Hospital May 4th Died May 16th from Erysipelas of Head

External description. Body well nourished Rigor Mortis present the legs abrad on the arms & neck Skin over abdomen in the Iliac regions of a greenish color also a small green point in the right Hypochondriac region above Navel Skin in upper portion of Thorax of a slightly yellowish tint. Upon separating trunk neck the upper portion of Thorax legs both ant. & post surfaces there are numerous spots of a dark reddish color

On cutting into one of them red spots a very small amount of fluid blood appears.

Brain in the ley slightly anemic Face swollen. Covered with a dark brown crust. Skin beneath somewhat reddened

Over the left frontal bone is a large irregular ulcer. Extending to the bone A smaller one about the size of a shilling exists over the 2nd left sup.

Ulc. front. bone.
Amyl. disease.
Hepatitis (Syph ?)

angle of the Right Parietal Bone.
Head.

On cutting into Scalp which is much
of a deep red color a considerable amount
of bloody serum escapes
Pericranium very dense & heavy
Surface of Dura Mater somewhat
bloody. Arteries contain a small amt
of blood. Dura Mater thin veins of
the Pia Mater showing distinctly
through it
Brain 44 oz. Entire surface
of Dura Mater smooth & normal
Surface of brain soft & moist
Considerable amt of serum ef-
fusion beneath arachnoid
Veins of Pia Mater moderately di-
lated
Brain Small amount of
fluid in the Lateral Ventricles
Surface of Sagittal Suture
& Middle & Thalami Optici Sur-
faces normal in region and
present at ant. ends two small
oval elevations
On Section Tissue are seen to be made
up of gray Matter
Section of Hemisphere Showing
& Moist. Punctia vasculosa.

Moderately marked. Gray matter pale

Cerebellum. Normal.

Arteries of the base contain a small amount of blood.

Pons firm & natural looking

Medulla oblongata firm & natural

Thorax & abdomen

Omentum tolerably fatty veins in it full transverse colon distended with gas and high up in the left hypochondriac concealing the liver in this situation

Intestines dark green in color

Diaphragm corresponds to the fourth rib.

On opening thorax. Pericardium concealed by a layer of fat.

Lungs also concealed by small adhesions

On opening pericardium a few drams of colorless serum noticed. Along ant. border of right ventricle was a series of minute ecchymoses. Patch of adhesion size of a shilling over centre of right ventricle

Small amount of fat in course of coronary vessels which were

distended with blood.

Right auricle Opened ℥iiss of blood semi-liquid & grumous & a large and colorless clot.

Right ventricle. Large and colorless clot extending into the Pulmonary arteries as far as the third bifurcation also ℥ss of liquid blood

Left Auricle ℥iiss fluid blood & a large colorless clot

Left ventricle contains a large colorless clot also. Weight of Heart ℥viiss

Valves. Mitral & Tricuspid - of normal size

Lungs. 40 ℥

Crepitant throughout. On section a large quantity of frothy serum mixed with blood exudes

No nodules Apices without cicatrices.

Small amount of natural pigmentation over lungs

Spleen ℥xii

On section dark purplish red color soft friable & contains a moderate amount of blood.

Scattered over surface of section are seen numerous translucent points about the size of a large pin head. These correspond to the enlarged

Malpighian Corpuscles. The application of Iodine demonstrates that these corpuscles undergone Amyloid degeneration

Kidneys.

Left Kidney 3 x ½. Right Kidney 3 x. Capsule leaves with a small portion of the organ leaving the surface slightly granular On section cortex of normal proportion Pale Malpighian Corpuscles faintly evident. Pyramids darker in color than cortex & contain somewhat more Blood.

Bladder. Contains 3½ fluid-urine Mucous Membrane walls, Thickness healthy. Pelvis of Kidney contain a few small Ecchymoses.

Liver 78 Oz.

Of an Elongated form measuring in length Extreme width of left lobe 8 inches Right lobe at gall Bladder 6 inches across. Somewhat more at extreme right border Capsule somewhat thickened Especially in neighborhood of the Longitudinal Fissure 4 or 5 pinkish Cicatrices over the surface of the organ

surface. - Color dark brown. Haem
orrhages recent & scattered under
neath the capsule. Gall Bladder
projects half an inch from the mar
gin of the organ - No gall stones

Small Intestine

Very dark in color mucous injected

Large Intestine

Similar color Mucous Membrane healthy Glands of Peyer not affected

Stomach

Mucous Membrane soft thickened Tranby born. Rugae still present Veins very full Considerable amount of blood in Vessels immediate neighborhood

J. Mills Bell

Case 6th May 20th/76

Infant found dead
Female child length 19 inches
Girth round chest 10½ inches
Epidermis readily detached of a bluish
color and in the groins & axillæ of a dark
& the skin covered with minute eczema
Navel not projecting 6 inches of umbili-
cal cord attached of a reddish color
No signs of cord having been ligatured
On section of cord umbilical vein seen full
of blood partly coagulated
Substance of the cord is of the usual
Glutinous appearance
Head. Long Diameter 5 inches. Over the bosses
from ear to ear 6½ inches. Head somewhat
conical in form projecting posteriorly
Skin very loose. Hair scanty & of a brown
color Bones of the skull exceedingly loose
& readily overlapping
Eyes closed - the pupils evident
No foreign bodies in either mouth or nose
Nails fully formed on the hands - not
projecting from tips of fingers
Sebaceous imperfectly developed & deeply
imbedded in the surrounding skin
On Right side of thorax near margin of
ribs are two superficial excoriations
No orifice found in either epiphysis

Atelect. lungs.
Fluid in periton.

at the lower end of the Femur not in the Epiphysis of the upper end of the Tibia
Abdominal & Thoracic Cavities

On opening the abdominal cavity a bloody fluid exuded about ¾ of the existed in the Peritoneal Cavity.
Diaphragm corresponds with the fourth intespace Portions of abdominal organs healthy. Liver does not extend to the Navel
On opening the Chest about ¾ of a bloody fluid is found in Pleural Cavity. Lungs of anterior Mediastinum infiltrated with Blood. Right Lung covers a small portion of the Thymus Gland. Its surface is of a pale finger breadth from the cartilages of the Ribs. The left Lung covers the Pericardium
Pericardium ~~Cardium~~ is covered by a small amount of fat. Its cavity contains about ¾ of Blood.
Heart. Pleura almost transparent
Right Auricle very much distended and of a dark Blue color
Right Ventricle also full of Clots.
Right Auricle contains a dark grumous clot which fills the whole cavity
R. Ventricle contains only a small amount of fluid Blood.
Left Auricle contains a dark grumous

Clot the size of a marble
Left Ventricle contains no blood.
Veins at the Root of the neck contain a
small amount of blood
On removal of lungs with Trachea
which had been cut previous to opening
of thorax it was found that on placing
them in a bucket of water that they
sank immediately. The Lungs are of
a dark brown color lobules distinctly
marked. The septa being of a very dark
color. On Section they do not crepitate
Lobules distinct dark & contain a moderate
amount of blood
Thymus Gland of average size
& dark purplish color on section
Larynx & Epiglottis stained by Post Mor-
tem imbibition. Tissues in Neighborhood of
Epiglottis infiltrated with bloody ser-
um otherwise normal.
Spleen. about 3/4 X 1/2 an inch dark in
color. Upon Capsule are a dozen or
more white patches which to the touch of
the knife feel somewhat softer
Supra Renal Capsules very soft distinct
cortex & Medulla obliterated
Kidneys lobulated dark in color
No distinction between cortex & Medulla
No appearance of Uric acid Calculi

Liver soft flabby. Capsule presents in one or two places on upper surface & more or less the same opaque thickening as noticed on the spleen. On section soft pulpy & contains a moderate amount of blood.
Bladder large & contains a small amount of bloody fluid. Mucous membrane stained
Vagina. Contains a quantity of mucus
Os Uteri large edges irregular & fissured
Organ dark externally.
Ovaries normal.
Intestines.
Small intestines contain a bloody mucus.
Large intestine contains a dark reddish meconium walls thin & apparently healthy. (Several similar patches to those over liver & spleen seen on peritoneal surface)
Head. Bones of skull very loose overlapping readily & rendering it impossible to estimate size of fontanelles
Soft parts infiltrated with a bloody serum
Dura mater normal. Small amt. of blood in the longitudinal sinus
Brain substance soft pulpy completely broken down in the centre rendering an examination of it

quite impossible

Case 7th. June 17th 1876.-

Daniel Love. 30.-

Admitted 26th May.-

General appearance of body.- Body that of a large Man, firm muscles Skin at superior part of body pale anæmic. Rigor Mortis present in all the muscles. No adherence present Post Mortem discoloration in the posterior portions of the body.

Thorax and Abdomen small amount of normal fat.-

Position of intestines natural Right lung adherent to the sternum in front. small amount of fat over the pericardium. Pericardium contains 2½ oz of turbid serum slightly tinged w blood.

Heart- Moderate amount of fat at base & margins of right ventricle. Right Heart distended w blood. Rigor mortis absent- Slight degree of rigor Mortis in left ventricle Right Ventricle occupied by a large partly antemortem clot

Sub-peritoneal
Degen- of myocard.
Nodule (Cat.?) of lung.

Tubercular Peritonitis 24

Case 1st May 25th 76

John W. Tierney

Body extremely Emaciated. On the face the Emaciation is extreme Skin upon Thorax, upon Extensor surfaces of the Legs & to a less extent on the arms covered with small Ecchymoses. These also exist upon the face and upon the neck Skin upon the abdomen of a dark color (purple) Here & there small dark patches looking like fading Purpura Abdominal & Thoracic Cavities

56 oz of Bloody turbid fluid in which are flocculi of Lymph Intestines abdomen Substances a dark red color Here & there Matted together & irregularly covered with small white patches On closer inspection these small white patches, which are often aggregated together are seen to be subperitoneal a few Large flakes of Lymph varying size from a sixpence to a shilling are also seen over the intestines. The small white patches already referred to seem over the Mesentery & are abundant beneath the Parietal layer of the Peritoneum

The Intestine color with the Stom
ach are Matted together & the Liver
does not appear on Superficial Ex-
amination
Thorax. Anterior Mediastinum much
sunken. Lungs Mottled in color
The Right exhibits much fatty more
than the Left. Both are covered with
a thin layer of old Pleuritic adhesions
The tissue of the Pericardium is in-
filtrated with a small amt of yellowish
serum.
On opening Pericardium 3ss of thin
fluid was removed
Heart looks flabby. Wall of Right Ventricle
sunken. Valves well Marked patches of
attition. Evident. A small amount of
fat infiltrated with serum exists
at the Base & along the edge of the Right
Ventricle. Several Ecchymoses are
present on the Right appendix Auricula
Right Auricle Contains Hardly any
Blood.
Right Ventricle Empty.
Left Auricle. Hardly a dram of Blood
present.
Left Ventricle. No Blood present
Small discoloration Obtain each ventricle
Tricuspid valves healthy

Mitral valves healthy.
Aortic semilunar also healthy. Two segments of latter valves fenestrated
Lungs
Pleural Cavity Contained 44 oz of bloody fluid almost all on the right side. Pleural surface right Lung reddened congested & covered with flakes of recent lymph
Right Lung. Surface covered with recent lymph Lower lobe of the lung in a condensed collapsed infiltrated with a dusky purulent serum.
Portion removed sunk.
Upper lobe crepitant; infiltrated with a considerable quantity of fluid
Left Lung. Pleural surface covered with old adhesions. No signs of recent pleurisy. Crepitant in upper lobe. Base of Lower lobe also in a condition of collapse & infiltrated with a large amount of dark serum
At the anterior border of upper lobe is a firm broad [illegible]
On Section This is seen to be made up of a small cavity which looks like a dilated Bronchial tube, and one or two Caseous knots and pigment-deposit surrounding Lung in a state of solidification
No signs of Miliary Tubercle

Kidney (Right) 4 oz Left 4 1/4 oz
firm, capsule easily detached. Cortex
of right ~~are~~ several small purulent ~~deposits~~
Deposits in immediate neighbourhood of which
substance deeply congested. ~~Organs very firm & dense~~

Spleen

weight 3 V. Substance firm, dark red in colour

Liver

lb 2. 2½ oz. yellowish in colour, as if stained with bile pigments. Vessels contain hardly any blood. Substance soft- readily torn

Stomach

contained a quantity of dirty yellowish fluid. Mucous membrance soft, thickened easily torn. A small amount of P. M. staining about the vessels in the dependent parts. No trace of any cicatrices. Pyloric & cardiac orifices patent

Intestines & Peritoneum

Peritoneal surface, indeed, the whole peritoneum, visceral and parietal, except the portion over the stomach ~~and~~ was of a dark red colour infiltrated and readily detached from the subjacent muscular layers. Localized flakes of lymph, ranging in size from a sixpence to a shilling covered here and there. The whole membrane presented a great number of small white areas, flat, not projecting above the surface, subperitoneal, & ranging in size from a hemp seed to a split pea. As a rule they were isolated but here & there groups were seen. They existed in about equal numbers over the intestines mesentery and parietal peritoneum. Beneath the latter were from eight to ten larger white patches which in section were

seem to have a diameter of 1/4", of a white caseous appearance, tolerably firm to the touch, and not encapsulated Intestines (small) themselves appeared pale, the walls thickened due to swelling of both mucous and serous surfaces On opening the large amount of a dirty yellowish faeces escaped. Mucous membrane dark in colour swollen, Peyers patches not enlarged. No ecchymoses.
Large intestine, contained large masses of yellowish solid faeces. M. M thickened.
Bladder & ureters appeared normal
Brain

weight Lb 3. 3½ Oz. Dura mater dense, not adherent Pacchinian bodies few in number. No clots in Long. sinus Arachnoid clear. Moderate amount of sub-arach. fluid Vessels of Pia mater full in the posterior regions.
On section a small quantity (3ii) of fluid in the lateral ventricles. 3rd & 4th normal. Septum lucid. & central parts of brain soft. White substance blood dots. glistening. Nothing abnormal noticed in the ganglia, or in the regions of the base

29 May 1876 1. pm.

Case VIII Grey degeneration. Sp. Cord

McLaghlin, 35. Divertic. of intest.

~~Chest~~ Gen descripn body moderate degree of emaciation, cheeks & mouth are much sunken, latter resulting from teeth removed. Considerable amt of long soft hair covers the body particularly the chest. A few ecchymoses exist over the ante. lateral part abdmn. Skin postern part body slightly discolored. Rig. mortis present in arms & jaws absent in legs

Abdmn

Abdominal & Thoracic Cavities. On openg abdmn the surface intestine appears dry. Coils small intest very small. Trans colon crosses a little below level navel. Unusual amt lge intestne below sigmoid flexure — fully 19 inches fr Σ flex to anus: this portion attached by a long mesentery.

Thorax Lungs appr exceedingly pale, like those of a child. Considrbl amt of fat over pericdm. No fld in pericdl cavity. Consd amt of fat over heart at base. resp. On openg rt ventricle abt 10ccm dk fld bld escapd. Vlves 3 cuspd similarly bltty. Rigor mortis in left ventricle, absent in rt. Left vents walls normal. Vlves healthy. Aort norml.

Lungs only abt apices along margin upper prt of lower lobe are small pigmentations. Numerous small ecchymoses exist over the lower lobe poster prt left lung. ~~Organs~~ crepitation all parts of lungs crepitant. The poster prts deeply congested, left lung especially so. Upper and anter prts lung seem emphysematous.

Spleen. wt 5½ ozs pulp tolerbly consistent. Surface mottled dk purplish color interspersd with white spots

Kidneys wt rt 5¼ oz lft 4½ oz. Capsule readily detached. Organs firm. Cortex pale. Lge vsls at base pyramids congested. Considble fat abt pelves.

Gallbldr distendd. Contng abt 2oz semi solid ~~gall~~ yellowish bile

on pressing G.B. none cd be made to pass out into the duodenum

Liver 52 oz wt firm ·tains · moderate amt · bld Surface section smt mottled fr hepatic ·gestion.

Stomach mucous membr soft ·gested in dependt part.

Intestines Jejunum presents ~~ab 10~~ diverticula (14) ranging in size from a pea to walnut occupying a position close to mesentery. mucous mem pale congested in places. m m of ileum swollen & soft. on lower portion ileum 2 small ulcers one small rnd size threepence shallow involving ~~Brain 50 oz wt~~ only submuc tissue m m in ulcr tumified and congested; other elongated in form abt size of bean, same chrs as former. Lrge intst ·tains · gatty dk brown feces m m Cæcum dk color here · there present few slight losses of substance.

Brain 50½ oz wt. Cerebellum 5¾ oz wt Bladder full urine mm apparently hlthy.

Case IX

May 31st 1876

Duncan McCallum

P.M. Thirty hours after ~~after~~ death.
General description of body. Tolerably muscular
man. Rigor mortis present. Dark brown
cicatrix exists above the ankles of both
legs one or two small patches of psoriasis
about the knees also a few about the elbows.
Cicatrices exist in the right groin

Integuments of the calvarium vessels of the
duramater nearly full. Longitudinal sinus
contains a quantity of dark grumous blood
Duramater dense glistening on inner surface
Vessels of pia mater moderately injected,
chiefly the veins. Arachnoid in the course
of the vessels somewhat cloudy and a con-
siderable amount of subarachnoidean fluid.

CASE OF CEREBRAL ANEURISM.

By John Bell, A.M., M.D.

On the morning of May 29th Mrs. R. was found by her children lying speechless in bed. She was 40 years old, was married at 21, and had borne five children, the youngest of whom is now 15. She was of medium height and rather thin. It was said that she was sometimes abused by her husband, who beat her about the head, and finally left her to earn a living by washing. She was rather peculiar in her habits, often doing little during the day, and then sitting up till two in the morning to finish her work. She occasionally suffered from vertigo,—a very severe attack seizing her on rising from the wash tub about two weeks before her death. Her sight left her for the time, and she afterwards complained of her head aching as if some one were pounding it. Her memory was very bad. She frequently was unable to recollect where she had left things. I found out after her death that for about a year she had been very deaf, and that her hearing had become much worse during the last two weeks of her life. She was not very strong, but had never suffered from any acute illness. She was a very temperate woman.

Seeing her about 8 a.m., I found her lying rigidly extended on her back with her arms at her sides, and the thumbs strongly flexed across the palms. Her countenance bore a stupid staring expression, and the pupils were moderately dilated and of equal size. The conjunctivæ were not sensitive on being touched. The thoracic, abdominal and pelvic organs were all healthy as far as could be made out.

After administering a dose of potass. bromid. and ext. valerian. fld. and rousing her up, she seemed slightly conscious on being spoken to, and the pupils were then sensitive to light. During the day she became still more conscious, and her eyes followed those moving about the room. She passed water freely, and her bowels moved from the effects of a dose of croton oil. Ice had been applied to her head, and bottles of warm water to her feet, which had now become very warm.

In the evening she became worse, and more insensible,

Case IX Cerebral Aneurism

twitching and moving in a restless manner. The same treatment was continued, with the addition of ext. ergot. fld. to the mixture. Her urine was drawn off by catheter and examined, but contained no albumen. She slept or dozed for considerable intervals during the night and until her death. On Sunday the 28th she had complained of headache, and was more nervous than usual.

The next forenoon, 30th, she seemed better than she had been the previous evening, but was utterly unable to speak. Her left arm and leg were found to be completely paralysed, and later in the day became quite dark in color. She was unable to close the right eye.

She took beef tea and milk in small quantities, and was ordered to have brandy if there were any signs of sinking. In the evening she became decidedly comatose, with bellows breathing and accumulation of mucus in the larynx and trachea. There were now no convulsive movements. She died at 11.30 p.m. on the 30th.

It was thought that an extravasation of blood had taken place in the anterior portion of the right hemisphere.

Post mortem, by Dr. Osler 11 hours after death.

Body that of an average sized poorly nourished woman.

Head.—Nothing special noticeable about the soft parts or the calvarium. Veins of the pia mater moderately full of blood; subarachnoid fluid scanty. In the removal of the brain, clots were met with in the neighbourhood of the middle fossa of the base of the skull on the right side, and they were seen to have proceeded from a large extravasation which had taken place in the right Sylvian fissure. The convolutions of the middle lobe in the vicinity were considerably lacerated, the brain tissue broken down and replaced by a dark clot. About a handful of coagulated blood was removed, most of which was in and about the Sylvian fissure. Only a thin layer of blood existed in the base, around the optic commissure and perforated spaces. A delicate coagulum also extended over the convolutions in the lateral region on the right side. The circle of Willis and middle cerebral artery were removed for subsequent examination. The sub-

first administration of salicylic acid, with about 60 grains of the medicine and completely annihilated in 4 days with about 220 grains. I trust that if such satisfactory results can be obtained from this drug, that it will be brought into more general use before long. Judging from the results given in all the reported cases which I have seen, and the most satisfactory termination of my own case, it seems to me that salicylic acid in the treatment of acute inflammatory rheumatism, possesses the following advantages *over any other* plan of treatment that I have ever seen adopted.

First.—It arrests the progress of the disease and gives permanent relief from pain, tenderness, &c., in a much shorter time.

Second.—If used early before any cardiac complication exists, it will by its prompt arrest of the disease, prevent the occurrence of such complications, and the consequent development of *organic* disease of the heart in many cases.

Third.—It does away with the necessity for using any local application.

Fourth.—No ill effects have as yet been known to follow its proper administration.

The irritation of the mouth and throat produced by it is rather a disadvantage, nor do I think that this would be over come, in many cases, by the use of capsules or wafer paper, as the majority of patients have a great antipathy to swallowing bulky substances, and particularly where they have to be used frequently. I found the thin gruel answer very well, and I think it will be found to do so in most cases, until some solvent is discovered, which will enable us to administer it in solution, in less bulk than any of those so far recommended. There are several mentioned in "The Druggist's Circular," for July, but there are objections to them.

PETERBORO, Ont. July 10th, 1876.

stance of the brain appeared healthy ; the ventricles were empty, and nothing abnormal was observed about the ganglia at the base. On carefully washing away the clots from the right middle cerebral artery, the source of the hæmorrhage was ascertained to be a small aneurism, situated in the fork of the chief bifurcation of the vessel. This had ruptured, and the blood had escaped through a large ragged orifice. The situation, size and appearance of the rupture are well shown in the annexed wood-cut. The remaining vessels of the brain were found healthy, no atheromatous change being detected in their walls.

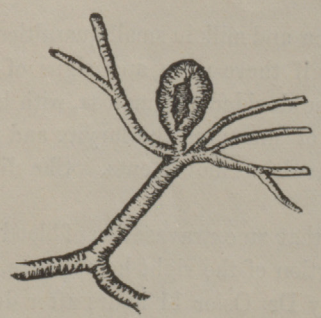

Abdominal organs healthy ; no affection of the kidneys.

A beautiful false corpus luteum was found in the left ovary, (she had menstruated exactly three weeks before) measuring fully $\frac{7}{8}$ of an inch in diameter, and with a pale yellow convoluted wall. The central coagulum was of a dark red colour. In the same ovary at the other end was a small corpus luteum about $\frac{1}{3}$ the size of the large one, with a decolorized coagulum and much more convoluted wall.

Uterus somewhat enlarged. Mucous membrane appeared congested and tumefied.

Lobar Pneumonia. ..... Meningitis

Case X. # June 1st 76

Henry Feldman aged ~~#~~ 38
Rigor Mortis present to a slight extent
in the arms less so in legs.
Body not Emaciated Muscles Mod.
developed Post mortem Body discolored

Abdomen & Thorax.

Position of abdom. viscera Normal.
No fluid in abdominal Cavity
Thorax. Lungs very much pigmented
Apex both of left Lung covers two thirds of
Pericardium is ready to contact with
lung of Thorax with No fluid in either
pleural cavity.
Right lung adherent at apex: cicatrices
Left lung also adherent slightly at apex
Diaphragm extent behind
Pericardium Sac contains about 3ii of fluid
in it
Heart Medium size. Moderate amount of
fat about the base. An undilated patch
of atrition over Right Ventricle
On removing the Heart a considerable
amount of dark fluid Blood & clots escaped
Right Ventricle contains semi a colorless, firm
Clot Tricuspid orifice of normal size

Fenest. valve.
Lob. pneum. R. u. lobe.
old infarct (?) of Kidney.
Ac. fib. meningitis.

Tricuspid valves Healthy. one segment ~~Fenestrated~~ Fenestrated

Left ventricle - A few small clots in it. one flat one extending up into the left auricle slightly

Aortic valves slightly thickened at the corpora Arrantii segments also ~~fenestrated~~ ~~a~~ fenestrated

Muscle of Heart - of normal appearance

Endocardium covering the Columnae Carneae somewhat cloudy

Lungs.

Right Lung upper lobe with exception of Ant. & lower margin in a state of Red Hepatization the cut surface presenting usual appearance of that condition. Bronchial tubes of hepatized area filled with plugs of lymph which look like small suppurating foci on superficial examination the rest of this lung & the whole of the left lung are in a state of Engorgement. and collapse evident over lower lobe

Scattered over surface of Pleura of both Lungs chiefly at the Bases are small white firm granules feeling to the touch like small shot. These look very much like Miliary Granulations. Some of these however are flatter not granular & they may be simply small fibroid thickenings of the Pleura

Spleen 8½ Oz. Soft. Pulp of a purplish red color semi-diffluent in character

Left Kidney 5 Oz.

Capsule thin readily detached
On section the organ contains a moderate
amount of blood Proportion between cor-
tex & medulla Natural

Right Kidney. 5½ Oz.

Similar characters to left.
At the lower part of one Pyramid is a small
white firm nodule about the size of a
pea. No miliary granulations over the
surfaces.

Stomach. Mucous Membrane pattern
Oct with branching red points In
places there are minute Ecchymoses.
Towards Pylorus end there is a patch where
Mucous Membrane appears infiltrated with blood

Intestines.

Mucous Membrane of Duodenum
& Jejunum Healthy In the Ileum
Peyers glands plainly marked Pigment
at the bases villi in the region of the
Intestine look dark = fatty degeneration

Liver 55 Oz.

Contains considerable amount
of blood. Healthy

Brain 48½ oz.

Under surface of the Brain
Longitudinal Sinus filled up with
a thin layer of Yellowish white Lymph
A similar condition exists in the Sylvian
fissures. In the Right Sylvian fissure
the layer is very thick. A thick layer of
the same character exists around the
Optic Nerves and extends over the Pa
foramina Spaces in the Pons and on either
side to the under surface of the Middle
lobes. Continuing from this it extends
as a thick layer Posteriorly over the Pons
Medulla & contiguous Portions of the Cerebellum
Extending laterally it lines the lower and
anterior edges of the Cerebellum as a thick
Serous white layer. Behind the Medulla
a similar condition exists and the Lymph
extends to the groove between the lobes of the
Posterior surface of the Cerebellum

Superior Surface of the Brain

Vessels of Pia Mater
moderately full. A considerable amount
of Serous Yellow Lymph exists beneath
the arachnoid of both anterior lobes
A slight amount is seen along the ventricles
over the Posterior surface
over the Convolutions of the left Posterior lobe
a thin layer of Sclerosation exists.

Tint of a uniform dark red color due to some effusion of blood from the vessels On Section the white substance is glistening & moist. Ventricles moderately marked Fornix & Septum exceedingly soft - Breaking down on attempting section

Ventricles contain a moderate amount of fluid. They appear slightly distended & their walls are soft

Here & there in the course of the vessels small Extravasations are met with

Small extravasations are also found along the vessels in the fourth ventricle

Arachnoid interposition involved in the inflammation and is thick greyish yellow in colour. No trace of miliary tubercles to be seen on superficial examination either about the base or along the vessels in the Sylvian fissures

Few valves.
Chr tub. pul.
Nutmeg Liver
Ulcers of Col. & H.
Gpt of 3 cent.

Case XI. Phthisis

Body considerably emaciated; hair
brown long dark & straight
On opening the Thoracic Cavity: Lungs
appear pale in colour & full volume
In the abdominal Cavity the liver & kidneys
much below its natural limits

Heart: Valves healthy tricuspid
orifice somewhat larger than normal
Aortic Valves fenestrated muscle
somewhat paler than natural

Lungs: Right at the apex a large
irregular cavity exists - about size of
a large fist - this communicates with
several small cavities in the neighborhood
in the wall of the cavity the remains of
the vessels & Bronchi are seen. another
irregular cavity exists at the posterior
region of upper lobe behind the
upper lobe of this lung in front is
transformed into a dirty purulent
mass. in which small cavities are
formed in all directions through out
the remainder of this lung one

numerous small tuberculous nodules many of which on careful inspection are seen to present a central opening - bronchial tubes

Left lung the whole of the apex of this lung is transformed into several cavities containing a dirty sanious pus. The remainder of this contains scattered deposits of tubercle The lower anterior part of this lung is emphisematous

Left Kidney 5¾ oz. elongated in form capsule readily detached, cortex pale slightly increased in volume.

Right Kidney 5½ oz. similar in appearance to the other.

Spleen 9¾ oz. Very blue color externally pulp dark, soft, friable.

Liver contains considerable amt of blood Tissue soft easily torn. On section slightly nutmegged. No gall stones.

Intestines -

Contain a considerable amt. of yellowish faeces Mucous membrane pale Throughout the illium and jejunum are numerous Ulcers, characters of which are as follows: They all lie transversely to the long axis of the intestine edges elevated

tumefied not much congestion in the neighbourhood though about some there is a zone of hyperaemia. The base of most are formed of tissue in which are imgumerous tubercles, and upon the peritoneal surfaces tubercle are seen situated upon pedestaled areas. The number of these ulcers is about 24 and vary in size from a sixpence to a half dollar

Large Intestines.

Mucous membrane at caecum thickened. Caecum presents an enormous ulcer fully six inches long very irregular outline and scattered about upon it are small islands of mucous membrane. Several other losses of substance occur throughout the colon. Mucous memb of rectum soft tumified and not ulcerated.

Brain — Dura mater dense, not adherent. Fluid blood and small clots in longitudinal sinus

Vessels of Pia mater - veins contain a moderate amount of blood. Convolutions slightly wasted; spaces between the vessels somewhat increased.

Ventricles contain about 3i of fluid. On removing the cerebrum interpositum a clear cyst filled with fluid was seen occupying the third ventricle, and connected with the cerebrum. It was about the size of an orange plum & the fluid was of a clear serous character. It looked at first like a cysticercus cyst but on further examination it proved to be a simple cyst. Structure of cerebrum & cerebellum apparently normal, as also the ganglia at the base

Case XII Gangrene of the Lung

Daniel Jones, aged 48

Thorax and Abdomen

On opening the abdom. cavity the stomach is seen enormously distended, extending below the navel, and far over towards the left iliac region. Liver extends about 2½ inches below the ribs in the mammary line. Very little fluid in abdom. cavity. Diaphragm corresponds to sixth rib. Capsule of liver — free edges below appear thickened

On opening the thorax the right lung collapses slightly left lung adherent and covered with a layer of plenitic adhesion. On removing this, the left lung is seen to extend for a considerable distance over the pericardium

On opening the pericardium ℥ij of citron colored fluid are found. The surface of the heart presents several well marked patches of attrition — one in the usual situation over the right ventricle, others along the course of the coronary vessels. In addition the visceral layer of the pericardium over the right auricle, especially the appendix, is much thickened & of a white colour. Similar thickenings exist around the inferior vena cava, and round 2 of the pulmonary veins.

Heart

On opening the heart a large amount of dark

Sang q flung
Dil q stom
Ac. adh. pleur.
fibros q pericard.
Atheroma.
Fenest. valves.
Mit & aort. Chr. (clen sudo.
Emphysema

fluid blood escaped. No coagula present. Rigor mortis absent

Right Ventricle — Contains a number of small pale muscular clots adherent to the columnae carneae. Valves healthy.

Left Ventricle — No clots. — mitral orifice large, edges of mitral valves somewhat thickened. Anterior segment atheromatous at the base. Aortic semilunar valves slightly thickened at bases, — one valve fenestrated

Lungs.

Larynx — Mucous membrane pale, slightly greenish below the vocal chordae (vocales). On squeezing the lungs a considerable amount of dirty ill-smelling purulent matter escapes, of a reddish colour. Mucous membrane of trachea dark & of a greenish colour.

Left Lung — On removing the left lung, the fingers accidentally tore the lung tissue in the posterior region above. After removal this is seen to correspond to a large area of gangrene. This occupied the middle third of the upper lobe behind and in size was equal to a cricket ball. On pouring water on the mass it is seen to consist of dark broken down lung tissue (looking like tags) adhering to vessels of bronchi.

On careful examn the remains of an old cavity were found situated superficially and at the upper part and as far as can be ascertained about the size of a walnut. The lung tissue in immediate neighbourhood of gangrenous mass was consolidated while the remainder of this lobe was infiltrated with a large quantity of serum. At the upper part of the lower lobe of

this lung, behind, was a small cavity about the size of a marble. The tissue around this to the extent of an inch and a half consolidated - a low form of pneumonia At the free edge of this lobe behind was a small cavity filled with a dirty purulent matter The extreme free border of this lung behind presents several small patches cavities, recent in origin, about the size of a pea — the lung tissue in neighborhood infiltrated in a state of grey infiltration. The middle lobe to a large extent is in a condition of purulent infiltration — the cut surface smooth & pale, and a large quantity of purulent serum exuding from it. In this a few small deposits of softening may be seen.

Right Lung. Very emphysematous in front the whole of the posterior infiltrated with a large amount of serum. Pigmentation throughout the lung of moderate amount for a man of his age

Liver 3 L X p. Presented nothing abnormal. Contained a moderate quantity of blood

Spleen

3 V III. Lobulated, three fissures extending into it. Pulp dark in colour & of moderate consistence

Kidneys.

Intestines. Full of greenish yellow & very fetid fecal matter. No ulceration. a few ecchymoses in jejunum

Bladder. contains a small quantity of serum. mixed with mucus

Brain 3 X L II. Dura mater natural not adherent. No clots in longitudinal sinus of Pia mater cont. air & Cut. surf of rt. hemisp. a slight exudation of blood has taken place. Brain substance healthy looking No fluid in Vent.

Acute Brights Disease

Case XIII June 17th

Daniel Love. 30

General appearance Body that of a large man firm muscles Skin at inferior parts of body pale - anemic Rigor mortis present in all the muscles No oedema present.

Post Mortem discolorations in the posterior portions of the body.

Thorax and abdomen Small amount of mural fat. Position of the intestines natural Right lung adherent to the Sternum in front. Small amount of fat over the pericardium Pericardium contains 2½ oz of turbid serum slightly tinged ⊆ blood Heart Moderate amount of fat at base and margins of right ventricle Right heart distended with blood Rigor mortis absent Slight degree of Rigor mortis in left ventricle Right ventricle occupied by a large partly ante mortem clot

Tricuspid valve healthy Orifice natural size. Pulmonary semilunar valves healthy.
Left Ventricle. Contains small firm clot—colorless adherent firmly to the columnæ carneæ Mitral valves healthy. Aortic semilunar also healthy Slight deposit of atheromatous change exists at commencement of the aorta.
Weight of heart 13 oz

Lungs Right Lung. Crepitant throughout Pigmentation Moderate Hypostatic congestion in the posterior regions On section large amount of frothy serum mixed ⊆ blood Exudes Bronchial mucous membrane injected. Minute bronchi contain frothy serum mixed ⊆ blood Tracheal cartilages abnormally ossified in the right lung Or
Left Lung Crepitant Small cicatrix at extreme apex.
Two Another larger flat cicatrices at posterior part of apex On section a large amount of frothy serum exudes Post. parts of organ congested

Atheroma.
Hypo. cong. of lungs - &c
Scar of apex.
Acute nephr?

Kidneys Right. 11 oz. 4 dr. 1. Organ soft flabby. Capsule very thin readily detached. Surface of organ dark red color mottled with irregular small white areas appear on the surface around these is a zone of congestion. On section these white areas extend into the substance of the Kidney. They probably represent spots where the proliferation of the Epithelium of the tubes has been so great as to drive the blood from these spots. On section. the organ is seen to be of a dark red color Cortical portion much swollen & presenting alternating lines of white and red. Malpighian capsules very evident in places Pyramidal portion of an uniform dark red A few ecchymoses noticed in the calices of the pelves

Left Kidney 9 oz 3 dr Capsule thin Several appearances same & large irregular elongated white area is apparent on the surface of this kidney. It also has a zone of hyperaemia

On section it appears pale somewhat. mageshapell and the peripheral part somewhat lighter than the centre there other smaller patches like this appeared in the organ Cortex much swollen Mottled same general appearance as in the other organ

Splen 5 1/2 oz. - Soft Capsule slightly opaque Malpighian corpuscles quite evident Organ fissured

Liver. 62 1/2 oz Gall bladder projects 1/2 inch. Capsule thickened slightly in upper surface Organ much discolored dark at ant portion below Portal vessels full of blood. Bile vessels also full Under surf much congested in patches

Stomach Small Rugæ present Mucous membrane swollen Easily torn Capillary congestion in parts a few ecchymosis

Bile duct Full of bile.

Ductus communis free

Duodenum normal

Nothing abnormal in the jejunum

Intestines. Peyers patches small marked. Glands slightly salty and dark at base. Veins of ileum full. Mucous membrane somewhat dark. Solitary glands evident in Caecum. Mucous membrane soft & veins full in Colon. Bladder contains 5 oz of dark turbid urine.

Brain. 3 lbs 3 oz. On cutting through the soft parts a large amount of dark fluid blood escaped. Dura Mater dark. Blood in Longitudinal Sinus & one or two vessels of pia mater moderately full. A considerable amount of serous fluid beneath the arachnoid. Slight opacities in the arachnoid along the courses of the small convolutions of fair development. Sulci tolerably deep. Brain on section of average firmness. White matter glistening dry. Ventricles contained a few drachms of fluid. Do not appear dilated

Cerebritis

Fenestræ vahrs.

Cysts of Kid.

Papill. of Stom. Lit.

No softening of walls Veins in post cornua full Nothing abnormal noticed in the other parts of the brain

Cerebritis (?)

Case 14. Kidd - 60.

Body. that of a tolerably well nourished man. Lod [illegible] Post mortem lividity very evident in dependant parts. Slight yellow tinge of face.

Thorax + Abdomen

Intestines distended & fas. Adhesions in left lung.

Heart

3iv clear fluid in pericardium. About 3ij of dark blood in each ventricle

Unimpaired valves healthy Pulmonary Semilunars normal [illegible]

Left Ventricle 2 small cartilaginous plaques

Left ventricle Mitral valves healthy a little thickened at bases + edges

Aortic semilunars normal. Coronal large [illegible]

Walls of heart [illegible] of natural ordinary thickness. Muscular fibre pale.

Left lung. Pleural ~~transparent~~ except at extreme base behind which is in state of collapse. ~~Posterior part~~ dependent parts in state of extreme congestion. Anterior parts of upper lobe emphysematous ~~lobules~~ cicatrices at apex. Pigmentation in the upper lobe very significant. Chiefly in small round patches each the size of a threpence. Slight puckering at apex. Collapse at extreme posterior margin. Posterior dependent parts in state of extreme congestion. Cut surface becomes covered with a quantity of bloody frothy serum. Upper lobe emphysematous in front.

Spleen.

Weight 16½ oz. Pulp soft. Pyaemic. Dark purplish red colour. Malpighian corpuscles ~~not evident~~ Capsule not evident. Thickened

Kidneys.

Left 7 oz. Capsule readily detached. Pyaemic on section. Cortex pale. Pyramids however contain blood. Pyramidal whole substance are numerous small cysts. Pyaemic in size from small pin head to a pea. Most of them are filled with clear fluid in one or two fluid is turbid

Right 6½ oz. Same as other.

~~Kidneys~~

Liver. 64 oz. Firm. Pale on section.

Portal system will contain large quantity of fluid blood.

Stomach.—
Mucus membrane congested at dependant parts. Small Echymoses in fundus. Towards ~~the~~ pyloric end are several small projections of mucus membrane. the largest about size of small marble. Are probably small papillomatous growths.

Duodenum natural.

Jejunum normal. Peyers patches evident. Veins of ileum empty. Appendix vermiformis free & contains small quantity of mucus.

Caecum & colon healthy. Another small papillomatous growth size of pea exist in mucus membrane of sigmoid flexure

Pancreas — Weight 6½ oz.

Brain Organ did not fill sack of dura-mater. 3 oz of fluid escaped on removing the organ. Vessels of pia mater contain average amount of blood. Considerable amount of subarachnoid fluid over convolutions. Convolutions flat & wasted sulci wide. Ventricals contain a large amount of fluid. post. ventricles especially dilated. Veins of posterior cornua full In right are small extravasations along their course.

Fornix extremely soft even diffluent.

Cerebellum somewhat soft Nothing abnormal about it nor in the ganglia at the base of the brain Weight of brain 49 ℥.

Pneum R.d.l.
ac verme. 2ndo
Ac. fib. pleur.s (adhes.)
Croup. Colitis

June 19th 76

Case 15th. Pneumonia. (croupous. Colitis)

Mary Stewart Aged 22 years.

12 hours after Death. General decomposed body. Body that of a young well built woman. Skin pale. Discolorations on the dependent parts of the body. Large superficial excoriation due to a blister over the left Thorax or behind. Rigor Mortis present.

Thorax & Abdomen. Bulging abdomen organs Natural. Diaphragm corresponds to the fourth Interspace. On opening the Thorax Lungs of a pale rosy tint. Small amount of fat over the Pericardium

On opening Pericardium about 3ss of turbid fluid was removed

Heart Right Auricle filled with dark grumous Blood & one large firm Ante-Mortem clot. As continuation from this clot up the veins of the neck pericardium partially decolorized clot. Right Ventricle also contains a decolorized clot which extends up both pulmonary Artery

Left Auricle also contains a decolorized clot & some dark fluid Blood

Left Ventricle Rigor Mortis present

Tricuspid Orifice Normal. Valves Healthy

Pulmonary Semilunar Valves also Healthy.

Aortic Valve Tunica also Healthy. One segment Ossification

Mitral Valve. Slightly thickening at the edges & presents one or two Vegetations

Mucous Substance of Heart Healthy

Left Lung.

Marked lower Lobe & lower Portions of upper Lobe in a State of Red Hepatization

The Pleura covering this area of the Lung is injected & then & there covered with a layer of Lymph.

In the spaces between the two Lobes there is a thick layer of Lymph. On Section & cut surface presents the usual appearances of Red Hepatization. The apex of the Lung is much engorged

No Cavities at Apex of this Lung.

Right Lung. Traces at the lower lobe posteriorly an area of Consolidation the size of a Cricket Ball. On Section of this the tissue in the centre in a rounded area appears dark Purple & partially broken down. Remainder of lower lobe deeply Congested. The upper & middle lobes of this Lung pale & do not contain much blood especially at the apex & free margins

Between the lobes of this Lung are some old Pleuritic adhesions

Right Kidney. 3½. Cortex normal. Medullary Pyramids injected. Pyramids Vessels of Pyramids full. In one Pyramid is a small white patch half the size of a pea. Capsule slightly adherent at parts - a little opaque Renal Stellulae well marked.

Left Kidney 5½ Oz. Same Characters as the last.

Spleen. 7 Oz. Soft flabby. Organ contains a large amount of Blood

Liver 49 Oz.

Normal. Soft. Hepatic congestion very evident. Hep. Capillaries full. Area of Portal vessels pale.

Stomach.

Veins full. Capillaries of Mucous Membrane beautifully injected

Intestines.

Small Intestines Healthy Arrangement thin Walls velvet. Peyers patches Healthy.

Large Intestine Mucous Membrane Coecum M. M. injected & covered over in patches with a thin layer of dirty yellowish Lymph. The first twelve inches of the ascending colon presents nothing abnormal. The next eighteen inches the Mucous Membrane is congested

and covered over here & there with patches of Lymph. These patches are Elevated. The Edges overlapped. The Mucous surface and on removal of the Lymph it is seen that the process extends through the whole thickness of the Mucous Memb. Many of these patches are isolated - The Majority of them However run into one another and are arranged in a linear direction. Throughout the Descending Colon & the Sigmoid flexure small patches -(size of a sixpence) occur along the Mesenteric Border. The rest of the M.M. in this region is Spared. In the Sigmoid flexure there is a long irregular patch (4 inches in length) & the Lymph partially removed & the surface stained with the feces. Four or five the largest the size of a Quarter dollar. M.M. dark & much congested

<u>Uterus</u> 1 3/4 oz.

Of normal average size

Ac. ulc. aor. endoc perf. valve
Jct.
Ac. aor. ulc endo2
Dil q stom.
Ascites
Chi gastrc

Brain. 49½ oz.

Nothing abnormal about the Brain or Membranes. Sinuses also healthy. Vessels of Pia Mater full. Brain substance on section firm. Ventricles normal. Moderately well shown Cerebellum & Corpus at the Pons Normal

Aortic Valve Disease

Ac. ulc. endocard.

Case 16. June 20/76

George Wells æt. 60.

P. M. 13 hours after death. General description of body.— Body that of a well built man. Skin of face & upper part of trunk slightly icteric. Lower limbs oedematous. Pitting only to a slight degree. Skin of the legs of a dark purplish hue due to numbers of small extravasations. These ecchymoses petechiform in character. also exist in the triangles of the thighs, the flexor surfaces of the elbow joints, a few in the axillae

Abdomen and Thorax.

On opening the abdominal cavity the stomach is seen much distended extending in a curved direction towards the right and extending fully an inch below the umbilicus.

The liver extends fully three inches below the costal cartilages. Coils of the small intestine occupy the space between the stomach and pubes. About twelve ounces of a turbid reddish fluid removed from the abdominal cavity Thoracic cavity -

Right lung adherent in front to the pericardium and sternum. Left lung free. 3½ ounces of fluid in the left pleural sac. 13 ounces of a clear amber fluid in the right pleural sac. ℥ 3vii fluid in the pericardial sac. Heart appears large. fatty at the base & ventricular groove marks of attrition at usual site also at base & pulmonary aorta. Over the left ventricle. Cavities all appear distended with blood. Right auricle contains ℥ii of blood and clots. About ℥iii of clots & blood in right ventricle. ℥iii of blood & clots in the left Auricle. ℥iii of blood in the left ventricle. Right ventricle dilated Tricuspid orifice admits four fingers, valves healthy. Pulmonary semilunar

Left ventricle large dilated, walls fully 5/8 of an inch thick. Endocardium clouded Mitral orifice large. edges of valves thickened otherwise healthy. Aortic orifice semilunar valves covered with vegetations. In the extreme left segment a large mass of vegetation

extends down from ventricular surface. In middle segment the vegetations are flat & not so large; the remaining segment to 1/4 of its extent completely eaten away & the edges covered with numerous bead-like masses the remaining portion is perforated near the attachment of the valve. Endocardium beneath the valves much thickened. Coats of the aorta not presenting marked atheromatous disease. Heart weighs ℥xx ʒiii.

Left Lung. No adhesions, slight cicatrix at apex. Pigmentation moderate in amount. On section a large amount of frothy serum of yellowish (slightly) color exuded. Upper lobe & free edge of lower lobe crepitant. At the base the organ is intensely congested & in a state of spleenization ×

Right Lung adherent over a large portion of its extent & covered with a layer of thickened adhesions. Small puckered cicatrix at the apex. Also very oedematous. Middle lobe on section extremely dark colored, firm to the touch granular looking on section, small portions removed however still float.

Spleen ℥vi fissured and lobulated. On section firm. Trabeculae very evident. Two small infarctions of healing met with in the spleen. Capsule opaque thickened and over the surface small fibroid masses. ×

Right Kidney ℥v ʒi. Firm, capsule detaches with moderate facility, Section pale cortex appears somewhat wasted.

Left Kidney 7½ Capsule does not detach so readily. Appearances the same. Arteries at the bases of the pyramids very evident and those of the renal arteries somewhat thickened and atheromatous

Liver -

Firm to the touch, dark yellowish green mottled color. On section presents beautifully the characters of ordinary nutmeg liver; tears with difficulty. Weight 3 Lbs 11½ Gall bladder contains a quantity of bile. Ductus communis slightly obstructed.

Stomach -

Mucous membrane covered with a thick tenacious mucous, And also covered over with small partially decomposed echymosis. Mucous Membran soft easily torn.

Brain.

On cutting thro the soft parts on removal a cup full of blood escaped. Skull cap thick & deeply grooved for the meningeal arteries. Pacchionian depressions along the longitudinal sinus Small clot in the longitudinal sinus Pacchionian bodies large. Membranes very adherent along longitudinal sinus Extravasation thick & opaque & very adherent to the skull. Large amount of serum

quite ℥iii-℥iv escaped on removing the brain
Sulci deep. Arachnoid over them cloudy
Surface of brain somewhat pale veins not
very full. Brain substance tolerably firm
somewhat pale & glistening Ventricles
contain a few drachms of fluid, walls
a little soft. Sylvian arteries slightly
atheromatous. Pons Medulla & ganglia
at the base healthy.

Intestines.—

Nothing abnormal noticed
about the intestines. Appendix vermi-
formis small & attached along its whole
length.

ac. mil. Tb.
ac. " pleur.
" " Tb. g. Sp. & Kid. & peritan.
& liv. & Sp. meningo

Case XVII. General Tuberculosis. Sp. Meninges affected Mil.

Matthew Watson, sailor. age about 20
P.M. 36 hours after death
General appearance. Body slim, not well developed. no beard. Face thin. No external bruise or injury noticed. Rigor mortis present (s)
Thorax and abdomen. Opened.
Position of organs in the latter normal. Intestines dilated with gas, & are pale. P
Heart. Pericardium contained a few drachms of clear fluid. no patches of attrition. Right auricle full of dark venous blood, mingled with clots. Rt. ventricle also contains grumous clots. Valves - tricuspid & pulmonary normal. Left heart. very little blood in the chambers Valves healthy. Muscle substance slightly pale. Weight. 38½
Lungs.
Right - free. Left adherent, above. & in the removal a cavity in the upper lobe was opened. Right. Pleura somewhat opaque, & here & there a granular elevation was seen Lung crepitant. On section numerous miliary tubercles were evident throughout the whole organ. Most of these were small - millet like - a few were larger, size of no 8 shot One or two small caseous masses, encapsulated, noticed at the apex. A considerable amount of blood escaped on section especially at the dependent parts
Left. Pleura thickened in the neighbourhood of the cavity above mentioned & covered with old false membranes

A few miliary granulations observed on the visceral layer. none on the parietal layer on either side. On section this organ presented signs of old disease in the upper lobe The cavity which was torn in removal was about the size of a large walnut & had distinct walls. In its neighborhood were several small encapsulated caseous masses. The lung tissue in this area was much congested. Section Scattered throughout the whole organ were innumerable small tubercles, not aggregated together in groups. but diffused. as a rule they were clear & translucent

Spleen

Wt 1 lb. Capsule opaque. Organ firm. On section studded throughout with miliary granulations, which were very closely set together and gave a characteristic feel to the cut surface Tissue friable and did not contain much blood

Kidneys

. Left- Wt 5 oz. Capsule easily detached. No tubercles noticed on it. Surface smooth. light red in colour. On section one or two small tubercles observed in the substance. Cortex pale. pyramids injected. Right- Wt 5 1/4. Same condition as the other. Four or five tubercles in the substance, none on cortex

Bladder

contains a few ounces of slightly turbid urine. Mucous membrane and walls unchanged

Stomach

. Mucous membrane pale, (rennet pull) and covered with a slimy mucus).

Peritoneum

. No tubercles over the parietal layer. A few observed

in the Mesentery the glands of which were a little enlarged and tumefied but contained no tubercles

Small Intestines

Duodenum and Jejunum looked natural Solitary glands of Ileum swollen and the individual glands of Peyers patches were enlarged & the mucous membrane in the neighbourhood somewhat injected

Large Intestine.

Solitary glands of the colon were slightly enlarged

Liver. ℥ XL vi ℈

On section pale, larger vessels alone contain much blood. Acini with difficulty distinguished. A few tubercles noticed throughout the organ, some of these appear in proximity to the bile ducts, as a greenish yellow colour was evident about them

Gall-bladder contained a small amount of healthy bile. D. com. chol. patent

Brain ℥ XL ix ℈.

On the removal of the calvarium the brain substance was unfortunately injured and a large amount (℥ ss-i) of clear fluid, in part mingled with blood, escaped. Dura mater tense. Long. sinus contained a small clot. owing to the extreme softness of the brain it was with difficulty removed, & when placed upon the table became much flattened Arachnoid & cortex clear, and, especially over the sulci, separated from the pia mater by fluid. Large veins of the Pia moderately full of blood, but the convolutions themselves look pale and somewhat flattened. Arachnoid stretching from the post. surf. of the cerebellum to the cord. appeared somewhat

cloudy, but no distinct granulations were noticed. On examining the base the arachnoid over the medulla, Pons & that stretching from the Pons to the neighbouring convolutions was natural looking, and there was no lymph in the subarachnoid space Nothing abnormal noticed in the pia mater at the base, The frontal lobes convolutions were united to each other, and the convolutions on either side of the sylvian fissures were adherent, but easily separable with the handle of the scalpel & not a trace of lymph existed in either locality. Middle cerebral arteries & pia mater of sylvian fissures removed for examination. No tubercles noticed on superficial examination. None discoverable in the smaller arteries & ventricles. On cutting into the lateral ventricles, about ¾i of turbid fluid mixed with blood was found. Cavities much dilated, especially the posterior horns, which reached far back towards the cerebellum. The walls of the ventricles were excessively soft and in great part converted into a reddish white creamy substance, consisting of degenerated brain matter, blood corpuscles & "Glugi" cells. A gentle stream of water washed this layer off & showed the parts beneath rough, irregular & to the touch very friable
Septum lucidum soft & separated from the fornix in removal. Velum interpositum and choroid plexuses pale. No lymph or tubercles noticed. The former separated with difficulty from the corpora quadrigemina. Walls of the third ventricle soft but intact, commissures uninjured.
On & two small veins in the floor of 4th ventricle full.
On section of the hemispheres the brain substance appears soft, moist & glistening. Puncta vasculosa indistinct Ganglia at the base on section soft & moist. Pons somewhat

firmer than the remaining portions. Medulla pale.
Cerebellum. Consistency under par. White matter moist
any substance somewhat reddened.
Careful examination failed to detect any tubercles in
the substance of the brain
Spinal cord.
. In the removal the arachnoid stretching from
the cerebellum down the posterior surface was noticed to be slightly
opaque and granular. Laid upon the table the cord presented
at the lower part slight irregularities & bulgings.
Dura Mater. Thick & opaque. The parietal layer of the
arachnoid throughout the whole length of the cord was
besprinkled over with small miliary tubercles, like little
grains of sand. At the cervical portion they were less numerous than in the lumbar & dorsal regions. The cavity of the
arachnoid was empty. Pia-arachnoid As far as the
lower border of the cervical enlargement the visceral arachnoid
was clear & transparent, the pia mater could be distinctly seen
through it. From this point to the termination of the
cord in the sacral portion the arachnoid was opaque, and
the subarachnoid cavity filled up with a turbid lymph.
About the middle of the lumbar enlargement, and 4 inches below
where the Cauda Equina was the widest the arachnoid was
distended with an accumulation of lymph. By pressing
the pia mater by slitting up the visceral arachnoid it was
found in the dorsal & lumbar regions covered with a thin layer
of yellowish white lymph. About the nervous cords forming the
Cauda Equina this was very abundant, and indeed they
were all surrounded by a creamy soft lymph. which extended

to the termination of the cauda in the sacral canal.
About the upper part of the lumbar enlargment was an
isolated white mass which looked like an enlarged tubercle
it was attached to the pia mater but in section the contents
were soft & like the lymph coating the pia. Scattered over
this latter membrane were isolated miliary granulations
chiefly in the course of the vessels, & of small size. They were
most abundant below the cervical enlargment. a few
however were seen above this. The vessels of the posterior aspect
were full, in the anterior, empty. The cord especially in
the upper portion appear lightly embraced by the pia mater
so much so that the surface looked wrinkled, & puckered.
On puncturing the pia at the cervical enlargment the substance
of the cord immediately bulged out as a white rounded ball

Chr. tub. pul.
Oed.
Adhes. lungs
Mil. tb. of Splean
Ulcers of Intest.

2 3/6/06 67

Case XVIII Phthisis

General Appearance of Body ~~Considerably emaciated~~
Body that of a moderately built girl.-
Emaciation moderate. Slight post mortem discoloration in dependent parts of the body.- Skin thin. Superficial veins full. Skin of abdomen discolored - brownish & covered with Ludamina which are also present over the skin of the thorax. - Pedal edema - legs also as far as Knees. Rigor mortis absent. Linea Albicantes present
Thorax and Abdomen opened
Position of abdominal viscera normal
Liver extends very much to the left and is fully 2½ in. below sternal border in the mammary line
Four oz. of turbid fluid in the peritoneal cavity. Pericardium contains 1½ oz. turbid fluid.
Heart. 7¼ oz. - Right Auricle contained 1½ oz dark fluid blood. Right Ventricle contains about 1 oz blood. Tricuspid valves normal. Pulmonary valves normal
Left Ventricle ~~empty~~ contains only one small clot partially decolorized

Mitral valves healthy. Aortic semilunar also normal. Heart muscles soft & pale Patch of attrition over the right ventricle.

Lungs. — In fluid in either pleural cavity both lungs almost universally adherent. —

Left Lung. An irregular cavity about size of a large walnut in upper & anterior part of apex. This is in communication & several other smaller ones which reach quite to the apex. — The tissue in the neighborhood of these cavities is filled & small grayish masses. The whole of the upper lobe in this lung is filled & small grayish white masses. — Some of the smaller of these masses are clear & translucent & are undoubtedly miliary tubercles The lower lobe of this lung is congested. — here and there containing small cavities & caseous knots Over surface of pleura not covered & false membrane are small miliary granulations.

Right lung. — Covered in the greater part of its extent & a thick layer of false membrane This over outer surface of lung is marked

by the ribs and in this region is quite 4 lines in thickness. This thick membrane also extends between upper and middle lobes - firmly uniting them. - Lower ~~Over~~ Lower lobe pleuritic membrane slightly ~~thick~~ opaque but not so much thickened Numerous tubercles Exist over its surface The sections from apex to base along the posterior border show the tissue uniformly diseased. The apex almost completely occupied by a series of communicating cavities In no part of upper lobe does the tissue contain air. The border of middle lobe contains a few small areas of unaffected lung tissue. - Most of lower lobe except extreme border is infiltrated & these tuberculous masses. These are chiefly arranged in groups - the intervening tissue being consolidated.

Spleen 4 3/4 oz Tissue moderately firm - dark purplish red in color. . . Malpighian corpuscles indistinct scattered clear granular areas Exist throughout the tissue looking like miliary tubercles

Kidneys. - Left 4 1/2 oz. Capsule easily detached. Translucent no tubercles

Texture of organ firm. Coronary Malpighian Corpuscles ~~injected~~ Pyramids also pale - Cortical Right Kidney 4½ oz. Capsule readily detached. General characters same as other - No tubercles on surface.

Stomach Rugæ present. Mucous membrane pale & opt. Easily torn Covered in a small quantity of yellowish brown mucus.

Duodenum. Healthy Capillaries at edges of valv. conniv. - injected

Jejunum Filled in a small quantity of dirty brown like faces Mucous membrane slightly injected in places & presents ten typical tuberculous ulcers.

Ileum Mucous membrane slightly ecchymotic in places & presents about a dozen tuberculous ulcers most of them in jejunum & ileum about size of a penny & have thickened edges slightly undermined & bases of each made up of tuberculous matter Large ulcers in ileum are near the cæcal valve & Extend almost around circumference of the intestine.

Large intestine. Two small ulcers in caecum & about ileo caecal valve Rest in the colon. Peritoneal surface of intestines especially in neighbourhood of ulcers is covered with miliary granulations Mesenteric glands much enlarged & full of tubercles. Peritoneal surface of mesentery also studded over with tubercles.

Bladder. Healthy

Liver 5½ lbs. Large extending far over into left- Hypochondriac region left- lobe folded at edge Gall Bladder projects much below edge of liver and portion of organ immediately around it is atrophied.- Organ soft readily torn. On section hepatic Capillaries appear full. Periphery of lobules pale.

Brain. 40 Oz.- Considerable amount of blood escaped on removal of organ. Dura Mater thin.- Natural looking. Longitudinal sinus contains a small amount of blood and is clot- Veins of pia mater full. Surface of brain looks reddish.

Ventricles contain a small quantity of fluid. Choroid plexuses pale. Walls healthy. Central parts firm. Brain substance firm. Puncta vasculosa not excessively marked. Cerebellum & pons at base apparently healthy. ~~No~~ Neither tubercles nor lymph about base of brain or in sylvian fissures

Uterus

Small tubercles occur scattered through muscular substance of tubes. Os tincae edges a little fissured. Small grey granulations scattered over the surface of the ovary.

Fib y peric.
Petech. y pleura
Cas.ª y calcif.ª y pancreas

Case XIX Captn. J. C. Davidson, æt 37.

Rigor mortis present in slight degree

Examination 18 hours after death. Body well built muscular mass. Slight P.M. discoloration in dependent portions of the body. Marks of a vent blister over the epigastric region.

Thorax & abdomen:- Omentum somewhat fatty. Position of abdominal organs normal. Diaphragm corresp^d to 5th rib. In thorax rt lung xtends well over pericard^m. pericard^m and aurics well, auricle cov^d c fat. No fluid in either pleural cavities. Left lung adherent slightly at front and at apex.

Heart-

No fluid in pericardial sac. Patch of attrition on anterior surface of right ventricle. Cavities of right heart distended. Right ventricle full of dark blood and grumous clots, one decolourized, removed from the pulmonary artery. Right auricle full of dark fluid blood. Valves perfectly healthy. Left ventricle empty, no clots. Mitral and aortic valves normal. Muscle substance of heart of natural color. No rigor mortis.

Lungs. Left. Crepitant throughout. Pleura in the postero-lateral region covered with numerous small ecchymoses and several dark areas are evident, which on section are seen to be spots of apoplexy. There are ~~about~~ 5-6 of these ranging in size from a pea to a walnut. A longitudinal section of the organ revealed nothing abnormal, the dependent regions were deeply congested. On the parietal pleura of this side were numerous ecchymoses. Corresponding to the second rib & inter-

Costal space in the scapular region was an extravasation of considerable size. Right lung appeared somewhat more congested posteriorly than the other, and small portions of it felt firmer, denser and contained less air. These pieces, however, still floated on

Spleen, firm, not enlarged, dark purplish red on section

Tail of the pancreas adhering to it

Kidneys, surrounded with a considerable amount of fat. Capsules readily detached, surfaces smooth. On section, proportion between cortex & medulla normal. No congestion colour uniform, pyramids deeper than the cortex. Apices of pyramids of a brownish colour due to the filling of the tubuli with urinary salts. (urates). On squeezing a cone, whitish milky fluid exuded

Bladder

Vessels - veins & venules) full. About 3III of milky fluid in cavity. On examination this proved to be composed of innumerable epithelial cells from the bladder, a few columnar ones from the tubuli & ureters, Spermatozoa, and numerous small oil drops - like milk globules

Stomach, contained about half a pint of greenish brown baggy matter. No mucus noticed on the surface. Large veins full; small venules injected in dependant parts. No capillary congestion. Mucous membrane slate coloured somewhat tumified and softer than natural. No ulcerations or cicatrices. Cardiac & pyloric orifices natural

Small Intestines. No alterations noticed. Colour slate grey

No signs of congestion or inflammation in the mucous membrane. Faces in considerable amount ~~of~~ fluid and of a dirty brown colour. Puncta biliaria patent: bile flows on pressing the Gall bladder. Ileo-caecal valve and appendix normal Large intestine filled with dirty brown soft faces. No alterations noticed in mucous membrane

Liver.

Of normal size and colour. On section lobules indistinct parenchyma pale. Hepatic veins full, much blood exuding from them on cut.

Gall bladder much distended, extending fully two inches below the margin of the liver, and contained abnt. ℥viii of dark blackish green bile, which was in part inspissated

Pancreas, irregular in shape, and firmly attached both to duodenum and spleen. To the touch it felt rough and uneven and presented numerous white areas on the surface. On section these were found to be small caseous and semi-calcified lobules, some of which ~~were~~ had a dark pigmented appearance. The lobules in the interior of the organ looked healthy. No concretions noticed in the ducts

Brain. Dura mater normal. Long. sinus full of blood. Arachnoid on outer and base transparent. Sub-arachnoid fluid in considerable excess. Veins of pia mater, large and small, full. A slight cloudiness existed in some of the sulci on the anterior surface of the brain and a few suspicious looking granular bodies noticed upon the arachnoid (?) which might have been mistaken for miliary tubercles. On examination

they are found to consist of small aggregations of calcareous particles. a dozen or more of these were present. They were noticed in another case (Miss L-d-y). Organ on section firm, punctæ vasculosa distinct & a drop of blood exudes from each. Grey matter slightly pinkish in colour.

Ventricles. contain only a small amount of fluid; walls firm. Vessels of choroid plexus full. Velum interpositum natural looking, but Vena Galeni distended

Nothing noticable in the cerebellum, nor in the ganglia at the base. Medulla oblongata careful sliced, nothing abnormal noticed

Sympathetic System

Nerves & Ganglia of the Thorax & abdominal portion careful examined, no appreciable alteration

Pneumogastries

As far as could be ascertained, normal

Ac. pur. perit^{s}
Pelvic abscess

Acute Peritonitis from Pelvic Abscesses

6/7/76

Case XX. Louisa Armour Act 18. (3 3½ hrs PM)

Body that of a delicately built, but not emaciated girl. Abdomen distended, greenish color. Hypostatic congestion in dependant parts of body. Superficial veins well marked. Rigor Mortis ~~well~~ marked present in the legs, absent in the arms.

On opening the abdominal cavity ~~one~~ 3xxxvi pint of purulent fluid was removed. ; the omentum was closely adherent over the surface of small intestines and also adherent to the abdominal walls. On puncturing this just above the pubes a large pocket of pus was discovered lying immediately over the bladder. This was in communication with the peritoneal cavity. On removing the omentum the coils of intestine were found matted together by easily torn recent adhesions

Heart- Pericardium contained ℥p. of clear fluid, about ℥iii of fluid blood removed from the cavities. Right ventricle walls soft, a few small decolorized clots adherent to columnae carnae. Tricuspid valves healthy, somewhat stained by P.M. imbibition. Left vent. walls flaccid contains one small clot; Endocardium of a dark red color, valves healthy deeply stained by P.M. imbibition

Lungs. Right adherent throughout to the pleura, emphysematous throughout. A small

cretaceous mass found in the posterior part of the apex of the lung and another near the apex. Contains a moderate amount of blood, most in the dependant parts.

Left Lung.—crepitant throout. contains a moderate amount of blood. Posterior part two patches of a dirty greenish color not limited, the portion still contains air.

Spleen.— weight 3iiiss. capsule dense covered with a few old adhesions. pulp soft friable malpighian corpuscles indistinct.

Right Kidney 3 4/4. capsule easily removed venae stellatae very evident. On section parenchyma swollen, cortical portion particularly so, surface pale malpighian corpuscles congested and in the cortex alternating lines of red vessels & pale obstructed tubules are seen.

Left Kidney 3 3/4. capsule detached with difficulty on one side general characters same as the other.

Stomach— contained about ½ pint of dirty grumous fluid. Mucous membrane pale somewhat thickened, easily torn, layer vessels full, especially in dependent part.

Duodenum appears natural, a medium sized Ascaris found in it. which still lived

Liver — Surface covered with a layer of recent lymph, there are also old attachments between it and the diaphragm. Organ on section bloodless, lobules moderately distinct. Organ appears loaded with fat. Weight 3 LXIV. Small supplementary lobe attached by a narrow portion to the [illegible]

Brain — Duramater normal. Small clot in the longitudinal sinus. Vessels of the pia mater large & small full. Pacchionian

bodies distinct. On section firm, puncta vasculosa well marked. Lateral ventricles contain a small amount of fluid. Choroid plexuses natural looking. Vessels of the vela metapositum full. On removing the vela metapositum the third ventricle is not seen owing to the fact that the optic Thalami are united together over it. On section it was found that the union occupied an area somewhat larger than a sixpence. Anterior & posterior commissure distinct, no trace of middle commissure. Union is apparently by means of grey matter. Parts about the base appear normal, no lymph. Pons medulla & ganglia of the base normal.

Chr. aor & mit. Scler. endo $\frac{1}{2}$
Chr. mil. tub. pul.
Ac. tub. pyelonephr^{is}
tub. cyst^{is}
Chr. tub. meningi^{s} $\frac{1}{2}$

Tuberculous disease. Bladder. Pelvis of Right Kidney
Case XXI v. Lungs.
PM. 36. hours

John Murray. Died 15th July.
Rigor mortis present in legs not in arms. Great emaciation. abdomen black in colour, with ecchymoses scattered over the skin of abd. chest and anterior aspect of thighs. Axillary sinus also blackened

On opening the abd. cavity the diaphragm was found to correspond with the 5th interspace. Position of abdominal and thoracic viscera normal
Heart. weight - 3viii½. Right auricle contains an ounce of frothy blood. no blood in the other cavities. Tricuspid and pulmonary valves healthy. walls of right ventricle very thick ½". Mitral valves thickened at edges. Aortic semilunar somewhat atheromatous, presenting between two of the segments quite a large thick patch
Muscle substance apparently normal
Lungs. Slight adhesions on right side, extensive ones on the left. 4 oz of fluid in left pleural cavity. Upper and middle lobes of Rt. lung united by bands. Lung crepitant, save at apices. Rt. lung solidified for about 1" at apex & small cavity found in this patch upper lobe full of caseous masses. Remainder of organ hyperaemic and completely studded with miliary tubercle. Left Lung. Lobes of this organ united by adhesions. Solidified mass 2" in diameter at apex on it a cavity size of a pidgeons egg containing pus

Caseous masses Spinous ulcer excited in the upper lobe. Lower lobe congested & puffy tubercles large & small

Liver 3 XXXVIII ℔s. Extensively adherent to adjacent structures. A large grey sloughing patch on upper surface of left lobe. Vesicles containing watery serum excited beneath the capsule. On section colour normal, texture soft. and crepitant decomposition having set in. Gall bladder moderately distended, duct not obstructed

Stomach, contained an ounce of dark grumous fluid near pylorus was an ulcerated patch of mucous membrane with one beneath it

Left Kidney 3 VI ℔s. On post surface are seen three small tubercles, as large as peas, caseous in the centres Surface on section pale, pyramids well marked a tuberculous nodule, ulcer seen on post. wall of superior infundibulum. also several small tubercles scattered through the organ Left ureter normal. Right. Kidney 3 XIII ℔s. A uniform mass of caseous matter occupied the situation of infundibula calyces & pyramids, while the rest of the organ was completely riddled with large spots of caseous degeneration. The pelvis contained 3 II of pus. The ureter was as thick as the ring finger, the mucous membrane covered with caseous looking substance

Bladder. Pelvis contained a quantity of smelly looking urine, & on removal of pus the bladder

and rectum were found united by recent lymph, soft & easily torn. A large patch two inches in diameter, over the base of the organ was dark and thin and in the centre of this were two small perforations, through which the urine had escaped. The outer surface of the organ was covered with miliary granulations. A considerable quantity of pus was found in the organ & the inner surface was rough and irregular with tubercle in various stages of degeneration. Where discernable the mucous membrane was much thickened. Prostate contained a large cavity, caused by the degeneration of the tubercle it contained. In fact it was quite hollowed out a thin wall only was left.

Spleen healthy

Intestines. Nothing abnormal noticed in them

Brain

Dura mater, thick non adherent, no blood or clot in long sinus. Brain soft & flattened out when placed upon the table, so that perpendicular section was impossible. Veins of pia mater contained air. Arachnoid looked opalescent. A few scattered miliary tubercles at the base & on the left side on the middle lobe there was a large granular patch of tubercle, the size of a pigeons egg. Posterior to this, on the same side was an irregular depressed substance 1/2" deep, the base walls containing caseous matter. Puncta vasculosa indistinct

Report by Wm. T. Smellie.

Stones Bl. Op.
R. hydrothorax.
Collapse R. lung.
Cystic kidney.

Stone in Bladder. Lithotomy 84 18/7/76

XXII. Case

Robert Sullivan autopsy 18 hours P.M.
Rigor mortis present in legs. almost gone in the arms
Body much emaciated. Abdomen distended and
of greenish colour.
On opening the abd. cavity the intestines found much
distended, but of a natural colour, a faint streak of
redness here & there in the colon & adjacent coils. Lower
down in the hypogastric region inflammatory appear-
ances (even) present, the adjacent surfaces of the coils were reddened
& small flocculi of lymph were observed in the rectum
and lower portion descending colon & in the parietal
peritoneum in the neighbourhood. Very little fluid
in cavity. Stomach distended. Diaphragm corresponds
at the 5th rib
On opening the chest the right lung was found collapsed
lying in the posterior part of the cavity & not occupying
more than 1/4 of it. About 3ii of bloody fluid surrounded
it. no adhesions
Heart. 3i of serous fluid in the pericardial sac. No
patch of atheroma present. Weight 3 x 8. not rigor
mortis. pale in colour. Rt auricle contained a large
post mortem clot filling it & extending into the veins
Rt. vent. also small clot. & some fluid blood
Rt auricle empty. Walls of Rt vent. appeared thickened
cavity small. contained no blood. All valves
healthy. Muscle. pale. flabby & fatty. There was
an atheromatous patch around the coronary sinus
Lungs. Rt. 3x8. much pigmented. Crepitant.

except at lower border. General appearance healthy. Left. 3 x v. crepitant throughout; contains much blood. & mucus bathed with frothy serum

Liver

4 9 oz. firm, natural looking. Gall bladder empty

Spleen

3 iv ℥. Healthy looking

Stomach

much distended. & contained ½ pint of yellowish coloured fluid, with curd-like flocculi. M. M. looked healthy except in one spot near the pylorus where it was easily detached & covered with a greenish mucus In this are two dark brown patches - post mortem staining

Kidneys.

Right - 3 vi ℥. at upper extremity & inner surface was a large cyst, size of a walnut, it contained about 3 ℥ of clear fluid, organ appeared much congested. Right - 3 iv ℥. also looked congested much fat about the pelvis

Brain

47 oz. D. mater adherent. Lung. sinuses full of blood. Pacchionian granulations numerous, matting. skull. dura & brain substance veins of Pia contained air. Ventricles filled with an amber coloured fluid - clear. Substance firm Puncta vasculosa moderately evident

Intestines.

appeared healthy throughout & contained a large amount of yellow faces

Bladder, urethra, prostate & rectum were all removed together, & in the removal a small quantity of bloody serum & pus escaped. Nothing noteworthy was observed about the rectum, nor did the bladder show decided signs of inflammation but had very thick walls. The prostate appeared healthy but was small for a man of patients age It had been completely sliced through in the operation although the incision was carefully and properly made. Dr Emmick, who made the examination thought that this had resulted in infiltration tumor and had been the cause of death

Report by Dr F. S Mellen. M.a.

Ty. Ulcer. gastr. + hyperplasie

Case XXIII Typhoid Fever 24/7/76

Antoine Reinhart ætat 17. 20 hours PM.

Rigor mortis present in whole body. Body well nourished. Post mortem discolouration in dependent parts. Diaphragm corresponded to 5th rib

Heart

3 v 1 ʒ. Two drachms of fluid in pericardial sac. Cavities contained in clots. Valves healthy

Lungs

Crepitant. post. parts deeply congested & on section much frothy serum exuded

Liver

42 ʒ. soft friable. mottled in colour. Capsule not easily removed

Spleen. 3 x 1. congested. dark purplish red, soft

Stomach

Healthy, rugæ well shown. Empty

Kidneys R. 3 v i L. 3 1/4. Both apparently healthy

Bladder. distended with urine. Its mucous walls normal.

Intestines. Peyers patches were much inflamed & increased in thickness. Solitary glands also very evident. Some of the follicles had ulcerated

Friend waiting. no exam. of head.

Report by Mr T. Smellie

Carc. ventric. (Card. & less. curv. & univers.)

July 29th 88

Case XXIV. Cancer of Stomach. 36 hrs PM

Martin Henry, æt. General appearance- body extremely emaciated, and presenting in the face the peculiar hue of the cancerous cachexia, i.e. yellowish or sallow. Rigor mortis still present in the legs, absent in the arms. Skin over pectoral & abdominal regions of a greenish blue colour. On the left border of the sternum, just in a line with the nipple was a peculiar nodulent tumour, about the size of a robins egg, very hard, of natural colour & on section was found to not extend much, if at all, below the skin. Another the size of a bean was observed in the one mean line, three inches above the umbilicus, and a third, smaller, at the junction of the sixth rib with the costal cartilage.

Thorax & Abdomen.

On opening the body the diaphragm was found to correspond to the 5th rib. There was a small quantity of serous fluid in the abdominal cavity, and the liver & intestines were firmly matted to the stomach the appearance of which will presently be described. The liver extended further down than usual to the left side, and intestines in the vicinity of the gall-bladder were stained with bile. Lungs were considerably withdrawn on opening the thorax.

Heart- Valves.

On opening the pericardial cavity the usual amount of amber coloured serous fluid was seen. Rigor mortis still present in the heart, which was rather small. Small colourless coagulum in the ventricles. Little or no blood in the cavities. Valves healthy.

Lungs, both extensively adherent to the chest wall and diaphragm, mottled in colour. No nodules or deposit. Apices firmly adherent. Lower lobes of both lungs were congested, & much frothy serum exuded on section. Organs crepitant throughout. Lower lobe of right lung was so firmly adherent to the thoracic wall behind that it was torn on removal & in this region was a small hard concretion. Liver weight 3½ lbs.

Left lobe especially at its anterior border was firmly attached to the stomach a large white superficial patch, fibroid in character existed above the gall bladder. Organ firm to the touch, capsule came off with tolerable facility. On section, firm, bloodless not fatty, nor waxy. Gall bladder large, filled with bile. Ductus com. chol. patent

Stomach. This organ was found the seat of extensive cancerous disease. The cardia was so constricted that the tip of the forefinger could hardly be introduced. The cancerous thickening extended up the asophagus for a short distance and appeared in fact as an annular ring surrounding the orifice, the walls being fully ½" in diameter. Along the lesser curvature of the stomach to the distance of an inch or more the walls were thickened healthy but between this and the pylorus was a growth 3" long 1½" broad, ½" thick. Small nodules and indurations formed a string along the greater curvature. On the posterior wall was another large cancerous growth of considerable thickness. Pylonic orifice normal. Small nodules of warty character existed here & there over the whole serous membrane

Kidneys. Rt. 4½ oz. Lft. 3½ oz. appeard healthy. capsule easily detached. No congestion evident

Intestines.

healthy. Mucous membrane in lower part of large bowel was soft. thickened & easily detached from the subjacent tissues

Bladder.

Normal in appearance. Full of urine

Brain not examined

Pyaemia -
Petech. + Ecchymoses
Mediast. abscess.
Bact. in blood
Pl. + pul. abscess
Thrombus q.v. iliac

Case XXV Perinephritic Abscess. — Pyaemia

34 hrs P.M.

L. S. aged 11 female

General appearance. Body that of an ill-nourished, feebly developed child. Rigor mortis absent. On the skin of the legs, especially about the thighs, a few small punctiform ecchymoses are visible. Abscesses exist over both scapulae one of which had been opened — and on the forearms Left elbow was opened and found to contain a considerable quantity of thin but not offensive pus. Synovial membrane not ~~affected~~ eroded. On reflecting the skin over the left anterior thoracic region, pus welled up through a slight slit made near the sternum, and on removal of the latter an abscess was found in the anterior mediastinum situated close to the sternum and extending outside the cartilages of the 5 & 6 th ribs for nearly an inch

Position of thoracic and abdominal organs normal. No fluid in either cavity

Heart & Pericardium

. On slitting up the latter, both layers were found roughened with small papilliform processes which existed uniformly. No flakes of lymph on the surface about ½ fs of turbid, somewhat reddish fluid, in which a few flakes floated was removed

Valves & orifices of the heart normal. No endocarditis. Blood in right heart nearly fluid, only one small clot was present

Blood,

removed from the inf. V. Cava, and examined within two hours showed numerous rod-shaped. Bacteria. of the

Pleura & Lungs. Small amount of turbid fluid in in left pleura, and in removing the lung of this side, that portion of the membrane in the neighbourhood of the vertebral column, extending two inches in breadth was found in a state of intense inflammation, being covered with recent lymph, into and about which numerous extravasations of blood had taken place. An area corresponding to this in the visceral layer was similarly affected
Both lungs were full of blood in the dependent parts - hypostatic congestion - The right was crepitant throughout and free from pyaemic areas. The left contained one wedge-shaped consolidated spot, situated in the upper part of the free margin of the lower lobe in front. On section the surface was purulent, & a cavity was forming in the centre
Spleen
3 ¼ ins. soft & friable - dark purplish red in colour

On removing the intestines a large fluctuating swelling was observed in the region of the right kidney, behind the peritoneum, & tending downwards along the course of the Psoas muscle. A cut was made into it & about a pint of laudable pus removed. The situation of the abscess was behind and below the kidney, the lower end of which was also bathed in the pus. The Psoas muscle was infiltrated, its fibres degenerated and shreddy. The pus had passed down behind the pelvic peritoneum, & was in immediate contact with the walls of the bladder & vagina, neither of which were however perforated. The most careful examination failed to discover any diseased bone in the vertebra or pelvis

On slitting up the common and internal iliac veins the latter was found obstructed by a thrombus, which was closely adherent to its walls, and extended for a short distance into the common vein. The thrombus was firm throughout & no suppuration had taken place in it. The portion lying free in the common iliac was rough & ragged

Kidneys

right - somewhat flattened from before backwards On section the cortex presented a mottled appearance, pyramids injected, organ softer than natural. Mucous membrane of the pelvis presented numerous ecchymoses Left organ similar in general characters

Bladder.

Capillaries of mucous membrane injected in parts, ℥fs of urine - turbid -

Uterus and Ovaries, normal

Stomach,

contained a quantity of dark grumous matter M. M. soft, capillaries deeply injected in many places & veins evident from the discoloration about them

Intestines.

Beyond a filling of the capillaries in spots, nothing unusual was noticed

Liver.

Pale, and of medium consistence. No pyamic areas found. Veins of portal system tolerably full

Typh. fever.
Pneum: (R. l. l. lobe)
Head ulcers.

Case XXVI Typhoid Fever. 9 hours. P.M.

a.B. swede. at 23.

General appearance. Body that of a well ~~nourished~~ man
Musculature fairly developed. Sordes on teeth. No macula
present. Colouration of skin natural. Rigor mortis present
On opening the abdomen, the diaphragm was found to
correspond to the 5 interspace. Position of organs normal. no
appearance of peritoneal congestion. no fluid

Heart & pericardium

3ss of amber coloured fluid in the sac;
cavities of right heart ~~organ~~ appeared full. Left ventricle firmly contracted
Right auricle contained a quantity of dark semi-coagulated
blood. Rt vent. also full. Left heart. aur. small amount
of blood. ~~Left~~ firmly contracted. Valves. quite healthy.

Lungs.

Left crepitant throughout. Posterior part contained
much blood, but still crepitated & floated. Mucus & froth
mixed with blood ~~and~~ oozed on section. Right lung. The whole
of the posterior lobe of this lung behind was the seat of a
low pneumonia, the section was dark, moist, slightly bloody,
friable. ~~and~~ ~~pressed~~ portion sank at once when placed
in water. The rest of the lung was much congested. Apices
not shrunken. No fluid in pleural cavities. Pleura over the pneu
monic area injected, but no lymph present

Spleen. large. ~~3~~ X. soft. very friable, dark purplish red in colour
contained much blood, Splenic vein distended

Kidneys. somewhat swollen. congested in the pyramids. Cortex mottled
soft. Substance cloudy. Renal veins full. Pelvis & ureters
normal. Bladder. N. M. congested slightly. 3iv. of urine

Stomach. M. Membrana folded in rugæ, the crests of which were reddened. Two pints of dark grumous fluid in the organ

Intestines. As far as the commencement of the ileum no pathological changes were noticed. the M. M. was slightly tunnified and in parts congested. Fourteen typhoid ulcers existed in the ileum, three near the Valvula Bauhini in an advanced condition of ulceration, & with elevated congested edges. The upper four or five patches were not ulcerated, but the individual glands were swollen and infiltrated. The solitary glands were nowhere ulcerated, though enlarged & the apices of many soft & white. The M. M about the ulcerated patches though tunnified, was not congested. Ileo-cæcal valve unaffected. Appendix ~~very~~ long. apex free. attached however by small mesentery. Large bowel quite free from disease Mesenteric glands swollen.

Liver. 4½ lbs. very flexible. contained much blood in the large vessels. The portal vein, & all the mesenteric vessels were very full. Organ soft. not fatty.

Brain

Skin of scalp congested. Diploe also dark & full of blood. Dura mater normal. Sinus long. full. no clot. Vessels of pia mater full. No special injection of the capillaries Brain substance of moderate consistence. Puncta vasculosa well marked. Nothing special observed in the ventricles or in the ganglia at the base

Case XXVII Phthisis 12 hrs. P.M.

J. B. aged 65ys. male. Had had an epithelial growth removed from under lip weeks before

General appearance.

Typh. ulc.
Perf. 12" fr. valve.
Atheroma
Scar of duod. ulcer.

97 28/8/76

Case XXVIII. Typhoid Fever. Perforation

Section 15 hrs P.M.

- Black. Night porter at N.O.H. 14 days ill. Symptoms of Peritonitis 18 hrs A.M. at 40

Body not emaciated, of medium muscular development. Rigor mortis present in slight degree. Skin in dependent parts discoloured. No maculæ. Abdomen distended. Eyes open sclerotics dark at the angles of the

On opening the abd. cavity a considerable quantity of gas escaped. Diaphragm corresponded to 5th interespace. The omentum which lay immediately to view was somewhat fatty, & the vessels large & small deeply injected. On attempting its removal it was found adherent at its lower part, & required to be severed from the colon in order to be detached. The portion of the pelvis was covered with a layer of purulent lymph. The surface of the intestines was of a livid red, due to the injection of the small vessels & the parietal peritoneum was in the same condition. On carefully working down the coils from the duodenum no lymph or adhesions were found until the ileum was reached & here at the upper part in two places coils were closely adherent. On tracing the ileum towards the pelvis the chief seat of the inflammation was reached, the coils of the intestines in this cavity being matted together & covered with thick layer of yellow lymph, which on removal exposed the intensely inflamed vascular peritoneal surface. About a foot from the ileo-cæcal valve the perforation was found, with fluid faces of a yellow colour, flowing out & so revealing it. The entire pelvic peritoneum was acutely inflamed, & covered

with shreds of yellowish lymph. About ℥vi of dirty reddish fluid, mixed with liquid faces was removed from the pelvic cavity

Heart & Pericardium. A few drachms of clear fluid in the sac. Large patch of attrition on right ventricle. Left auricle & ventricle contained semi-coagulated clot, the upper layers of which were discoloured. Auriculo ventricular orifices and valves healthy, semilunar. ditto. A dozen or more small white elevations present in the aorta. Muscle of heart firm pale red colour. soft & flabby

Lungs

No fluid in the pleural sacs. Crepitant throughout; hypostatic congestion in dependent parts. Cicatrices in apices. A few small adhesions - bridles - at the apex & sides of left lung

Spleen ℥vii. Very soft. dark red in colour. easily torn, pulp like a jelly

Kidneys. Slightly enlarged, flabby. Pyramids injected. Bladder normal

Liver. Dull red in colour, section similar but paler. Portal vessels full. capillaries empty. Gall-bladder. natural

Stomach. contained a quantity of dark, ill-smelling matter M. M. soft: congested in dependent parts.

Duodenum presented a stellate cicatrix 1" below the pylorus. On slitting up the jejunum and ileum the M. M. was throughout pale. In the lower two feet of the latter were six or seven round deep ulcers; the largest about the size of a shilling was perforated. The whole M. M. of this part was thickened & tunified while the peritoneal surface was intensely injected & covered with lymph. The M. M. about the ulcers did not seem especially inflammed, nor were the edges elevated. No ulcers in the cæcum or colon. Appendix was obliterated for 1½". patent - the rest of it empty (1"). Mesenteric glands much swollen. Brain not examined

Pyaemia - Mult. abscess
Fibrosis of pericard
Ac. pleur. adhes.
Septic pyelonephr^{is}.
Pelvic abscess

Case XXIX Puerperal Pyæmia 8 hrs. P.M.

Norah. — æt. 18. delivered 3 weeks ago. Rigor mortis present.
Body that of a well built average sized girl. Skin exceedingly pale, Linia alba in abdomen, which was soft & not much distended
Left. groin dark brown, discoloured by 2 odour applications. A purulent depot opened just below the elbow-joint, ℥iii of pus escaped. Synovial membrane unaffected. Matter also existed in neighbourhood of left knee-joint. On making the preliminary incision pus welled out from the clavicular-sternal region on the right side and on the removal of the sternum, a large quantity flowed out from the lower part of the neck on the same side. Both sterno-clavicular articulations contained pus, no erosion of their cartilages. On opening the abdomen the stomach was seen enormously distended with gas, reaching below the umbilicus. Coils of intestines pale, natural looking

Heart.

about ℥i. of pale fluid in the pericardium. half a dozen small fibroid excrescences (♈) were found on the parietal layer. Cavities of the heart distended with blood. Rig. mort. in left. vent. Rt. aur. & vent. contained several ounces of clot, partially decolorized, & firmly adherent to the columnæ carneæ & musculi pectinati. Con. arteriosus & pul art. filled with a firm white clot. Left auricle also contained clot - semi-decolorized, while in the left ventricle the aur. vent. orif. was occluded by a firm closely adherent polypus, and another extended far into the aorta

Lungs

Crepitant throughout. Old adhesions on the left side. On the right, signs of a recent pleurisy, the membrane behind was injected

and lymph united the two layers. Both lungs congested posteriorly. (hypostatic)

Spleen ℥ VIII. Exceedingly soft & flabby. Pulp of a dark purplish colour. Splenic vein full

Kidneys. Both organs much enlarged. Lft. ℥X. Rt ℥XI. Capsule easily detached, & giving a smooth, mottled surface on which the veins stellate were very well marked. On section the cortical portion appeared increased in volume. Malpig. body indistinct, surface striated due to the alternate white & red lines (2) Vessels & tubes. Pyramids presented from the apices nearly to the bases, a peculiar white striated appearance, owing to the filling of the collecting tube with pus, which on pressing the bases, flowed out in drops from the orifices. Some of the pyramids were more affected than others, in some only the apices for 1/4" in others the whole lines extended to the base. Pelvis much injected, Ureters similarly affected. In the bladder was about ℥II of pus; the Mu. memb. congested. tumified, easily removed.

Liver

Apparently healthy, somewhat soft. Hepatic veins full. Bile vessels evident on cut surface

Stomach & Intestines

Nothing abnormal noticed in these organs

Uterus.

Was about the size of the fist, and as it lay in the pelvic cavity inclined slightly toward the right side. Immediately upon the brim of the pelvis, over the spine of the Ischium and extending from thence to the upper & inner part of the broad ligament was an collection of pus, about the size of a small orange. On opening it, the walls were found irregular, not defined & one or two smaller pockets

of pus, situated nearer the uterus were in communication with it. The plexus of uterinae veins in the bd. lig. and ovarian region were full & tortuous. No thrombi could be discovered in them. Organ on removal soft & flabby, cavity enlarged, no trace of placental site; walls everywhere lined by a thin dark red easily separable membrane, not smooth, but presenting little projections. Here & there the membrane was covered with blood. On section muscular walls soft; vessels numerous and a good deal of blood oozed from them cut-orifices. Of uteri swollen, distended, canal of cervix contained a viscid gelatinous mucus

Ovaries healthy. No corp. lutea of any age — perceptible

Case XXX Specimens furnished by Dr. Drake.

30/8/76 9 hrs P.M.

Case XXXI. Hæmorrhagic Small-pox.

Lad. æt. 9. died in Civic Hospital after three days illness Hæmaturia, & severe; Melæna, Hæmoptysis, abundant cutaneous ecchymoses. No small pox papules visible after careful inspection

Body that of a well built boy. Rigor mortis present to a slight degree. Face greatly disfigured by extensive subcutaneous hæmorrhage and dried blood scabs. Subconjunctival ecchymoses. The skin over the whole body was the seat of innumerable small extravasations, ranging in size from a pins point to a threepence. They were specially abundant on the thorax, lower abdominal region, & existed plentifully in the limbs. Panniculus adiposus well developed.

Position of abdominal and thoracic viscera normal

Heart & Pericardium

On slitting up the latter numerous ecchymoses were seen in the parietal layer. Several also in the right & left ventricles, but they were most abundant in the region of the anterio ventricular groove, & about the fat in this situation Right heart contained much dark fluid blood no coagula. Left chambers also small amount of same. No ecchymoses on endocardium Valves & orifices healthy

Lungs. No fluid in pleural sacs. Pulmonary & parietal layers of the membrane scattered over with small extravasations. Organs crepitant throughout; much congested at the bases where were two spots of apoplexy, walnut size, were found. On section small extravasations were met with scattered through the lobes.

Spleen, considerably enlarged, looking more like the organ of an adult. To the touch exceedingly firm. Capsule, somewhat opaque On section, surface dry, of a uniform dark red colour. On closer inspection a few Malpighian corpuscles were noticed as small

round white areas. There were however very few of them. Here & there were a few much smaller light spots, with dark centres ~~of blood~~ - Well. the general appearance of the surface was dark red. Splenic vein full

Kidneys.

appeared large. On section the pelves were found stuffed with semi-coagulated blood, which everywhere surrounded the pyramids A few small punctiform extravasations in the substance. Vessels also full. Organs of the feel firm & dense.

Liver;

. peritoneal surface scattered over with small ecchymoses Substance moderately firm. Large veins full.

The tissues in the retro-peritoneal region about the aorta, along the course of the lumbar nerves, and in the pelvis, were infiltrated with blood. No ecchymoses in the vessels themselves. The lumbar and mesenteric lymph glands looked like dark blackish red grapes, and on section, were uniformly hæmorrhagic, not a trace of normal tissue being visible

Case XXXII. Perforation of Cæcum. Peritonitis

M. G. ætat. 19. History of an attack three weeks previous to the present, spoken was called, strangulation, from which he recovered. Present attack dates from Friday the 27th. Symptoms those of general Peritonitis

Body that of a fairly well built young man, musculature of medium development. Panniculus adiposus sparse. Abdomen.

On opening this cavity the small intestines were found of a bright rose red colour, due to the injection of the minute vessels. On separating the coils, patches of lymph were met with in spots, uniting them together. About a pint of dark red fluid in which flakes of lymph floated was removed. The intestines were swollen & distended, their walls soft & tumified. On carefully tracing the coils from the duodenum towards the ileum the inflammation was found more & more extensive about the latter & in the neighbourhood of the cæcum. The small intestines were then removed & slit up. Nothing special beyond slight tumefaction of the mucous membrane, was found. Evidences of a bygone peritonitis were met with in the form of slight opacities & puckerings on the peritoneal surface, one of these visited on the epiploon & several others were seen on the parietal layer.

About the cæcum the lymph was abundant & the inflammation most intense. On carefully separating it from the abdominal parietes a round patch, 2½" in diameter, & a greyish red colour, somewhat depressed, was found. Corresponding to this centre of this was a round perforation of the cæcal wall, and the peritoneum about it was

rough uneven, & adherent to the abd. parieties. The cæcum was slit up and the mucous membrane found soft: unaffected, and presented the single ulcer already referred to. The perforation was round the edges thin, but formed of the M. membrane which gave it a punched out appearance Nothing unusual was observed throughout the rest of the large intestine

Heart. Right side contained dark grumous blood & clots. Valves & orifices healthy

Lungs.

Unadherent, slight hypostatic congestion. Organs crepitant throughout

Spleen

Slightly enlarged, pulp soft.

Kidneys

of normal size. Vessels of the pyramids pale. cortex somewhat pale.

Bladder.

contained about ℥viii of slightly turbid urine. Mucous membrane normal.

Brain not examined

Case XXXIII Typhoid Fever. 12 hrs PM

A-B. æt- 23(?)

Small, not very well developed body. Rigor mortis present in slight degree. Panniculus adiposus scanty. Muscles of a dark red colour

Heart & Pericardium.

℥iii of clear fluid in the sac. An irregular patch of attrition present upon right ventricle and another small one upon the left. about 1" above the apex. Cavities in the right side contained about ℥ii. of dark semi-coagulated blood. rigor mortis present in left ventricle which contained a small partially decolourized clot. Valves and orifices quite healthy

Lungs

No fluid in pleural sacs. R.L. inadherent- Left. attached by several strong bridles to the diaphragm no puckering at either apex. Very little pigmentation. Organs pale anteriorly, much congested in the dependent parts and of a dark livid red colour. On section from apex to base a large quantity of bloody serum exuded from the under portions and on the surface was scattered over with blood points - cut vessels. To the touch these parts were firmer, almost solidified, though still slightly crepitant The upper posterior halves of the were more affected in this way than the lower.

Abdominal cavity.

Position of the viscera normal. No fluid. Intestines pale in colour very little distended

Spleen.

3 X 1. dark purple in colour. Pulp of medium consistence. Malpighian bodies not visible

Kidneys,

of natural size. On section blood flowed from the vessels about the bases of the pyramids

Liver.

Soft. flabby. pale in section. Hepatic veins full.

Gall bladder, contracted almost empty. D. com. ch. patent

Stomach

contained about a pint of dark ill-smelling fluid

Mucous membrane congested at dependent parts; otherwise appeared natural

Intestines.

On their removal several intensely black patches were observed on the peritineal surface. These on section were found to be superficial not extending any depth. The ileum and jejunum were removed, a stream of water passed through & then slit up. The whole of the M. M. of the former was covered with a flaky yellowish matter which was closely adherent & removed only with great difficulty. The round punched out ulcer situated about 5' from the V. Bauh. & extended rather transversely to the long axis, and covered the area of half dollar. Two other small ones were close to it. The base was made up of the transverse fibres of the gut. With the exception of another small one about 3" higher up these were the only ulcers. The edges were not elevated, nor injected. The Peyers patches above this presented a dark brown appearance, flat, not elevated above the surrounding mucous membrane (which was also pale)

and on close inspection small white centres could be seen in them. The peculiar mahogany brown colour of these patches gave a very peculiar aspect to the mucous membrane. 8-10 of them were affected in this way. Higher up still were one or two which were simply hyperaemic. The solitary glands were scarcely visible. The peritoneal surface of the ileum was slightly injected & this part of the bowel looked dark in colour. Appendix contained a few semi-solid masses apparently faeces. Caecum. Mu membrane slightly injected. Colon & rectum appeared normal.

Brain not examined.

15/9/76

Case XXXIV Typhoid Fever. 10 hrs P M

Age. ab 40. In Hospital 5 days. Temp not high. Excessively timid & nervous. Body that of a large, somewhat corpulent man. Rigor Mortis present. P M lividity in dependent parts. Sudamina on abdomen. Mark of a square blister over epigastrium. Panniculus adiposus fully 1" thick over the abdomen

Thorax & abdomen.

On opening the chest, lungs of a pale colour and are almost in contact in the ant. mediastinum, completely covering the heart. Stomach protrudes in the epigastric region, & the omentum is heavily laden with fat. Several of the coils of the small intestine are almost surrounded with prolongations of fat from the mesentery

Pericardium, loaded with fat. About ℥iii of amber coloured fluid in the sac.

Heart. Right auricle & ventricle distended with blood partly fluid & partly of dark grumous clots. Tricuspid valves

healthy. orifice slightly dilated Left vent. contains a few small clots. Anterior segment of mitral valve slightly thickened at the free edge. Mitral orifice of normal size. Two of the aortic semilunar valves appear to have merged together, having a single sinus of Valsalva behind, which presented at the bottom an indistinct separation into two. Bases of the valves thickened and atheromatous, and the aorta for some distance also presents elevated white patches. Walls of left vent. somewhat thicker than natural. are soft.

Lungs

No fluid in either pleural sac. No adhesions. Slight puckering at the apices; both crepitant throughout; Anterior portions soft; air cells distinct and to the touch feel like dough or emphysema. Posterior portions contain much blood, which bathes the cut surface The lower lobe of left lung behind presents a considerable patch of collapse

Spleen. ℥ xv. Capsule thin and easily torn. Substance friable of a dark purplish red in colour. Malpighian corpuscles scarcely noticeable

Kidneys Right. ℥ vii. Much fat about the capsule. Renal vein full Section surface bloody, pyramids congested, cortex paler. Malpighian corpuscles visible. Capsule slightly adherent. Left. ℥ viii. Cyst. full of brownish fluid on the surface, about the size of a large pea. Organ in general characters corresponds with the other

Liver

lbs 4: ℥ 20. Left lobe much prolonged and thin. Whole organ soft, flabby. Surface mottled. Superficial veins stellate & full, especially on under surface of the left-

lobe. Substance excessively friable. cut surface of a dirty yellowish brown. Hepatic veins full. Capillaries of lobules contain only small amount of blood

Stomach

. Mucous membrane about the cardia congested, both capillaries and veins full. The rest of the mucous membrane was pale, & scattered over with minute ecchymoses. On careful inspection there appear to be small losses of substance, little pit-like Erosions: They do not occupy the same situations as the ecchymoses.

Nothing abnormal about the duodenum. On pressing the gall-bladder, which was almost empty a small quantity of whitish mucus escaped from the orifice of the D. C.

Jejunum. appears natural.

Ileum. Peyers patches distinct, slightly elevated above the surrounding M. M.. bases congested, but the hyperaemia confined to them. The semitransparent follicles very evident in each patch. Solitary glands in the neighbourhood of the V. Bauhini enlarged. In only one small patch, about 12" from the valve was there any trace of ulceration & in this it was not advanced In several places the mucous membrane presented a dark inky appearance, the distribution of which was exceedingly irregular. It was confined to the M. M. & in spots affected only the villi.

Coecum. M M. a little congested. Nothing abnormal in the colon or rectum

Bladder. contained 3 x of dark brown urine in which were floculi. M-M- appeared healthy

Brain not examined. Pat. a pr. case

20/9/76

8 hrs P.m.

Case XXXV. Pneumonia.

— Grunblatt aet 62. In Hospital only 10-12 hours

General appearance.

Body that of a well nourished, muscular old man. Rigor mortis present. Skin of a dirty brown colour & marked with P.M. discolourations in dependent parts. Superficial veins full & prominent, those of the leg varicose. Mouth sunken, front teeth gone. Hair & beard grey. Infra-costal margin prominent; deep pit in sternum above the xiphoid cartilage. Panniculus adiposus scanty. Muscles pale red. Costal cartilages cut readily & section yellowish.

Thorax & abdomen.

Liver extends 3 fingers breath below the costal margin, & gall bladder is evident beyond its free edge, indeed has caused atrophy of a portion of the free margin. Veins of omentum full. Stomach almost concealed by colon & liver. Caecum prominent from distension. Intestines pale. Lungs nearly meet in ant. mediastinum above and the free margin of the right is covered with a thick pleuritic exudation. Left lung also present two small patches of pleuritic exudation, and the lappet immediately over the heart is excessively emphysematous

Heart & pericardium

℥iv of clear fluid. Ecchymoses on parietal layer, a few also on visceral, & over the aorta a very large patch of attrition on right ventricle.

Heart appears large & full. Rt vent. occupied by a firm ante-mortem clot, which extends far into the pulmonary artery & in connection with another large one in the rt. auricle

much fluid blood also escaped on removal of the organ
Mitral valves healthy, orifice slightly dilated. Pulmonary
semi-lunar thickened and opaque at their bases
Lt. Vent. rig. musc. present. walls very thick; from decolorized
clot in chamber, filling up the mitral orifice, & extending into
the Lft. auricle & aorta. Mitral valves slightly thickened
at the edges, and opaque & atheromatous at their attachment-
especially the anterior one. Aortic valves thickened at bases
and corpora arantii. Sinuses of Valsalva large; whole
aorta appears somewhat dilated, & the intima is ather-
omatous throughout the whole arch. Weight 3 X 1

Lungs

Right. & tenaciously adherent at the apex & laterally
the former old & dense, the latter fresh & from a dense layer
of lymph over the antero-lateral region of the upper & mid-
dle lobes. Minute ecchymoses over the pleura & in the
adhesions. The whole of the upper & middle lobes, with the
exception of the anterior border from the apex down, is in
a condition of pneumonic consolidation, being airless
& portions sinking immediately in water. A section
through the diseased portion shows that the upper part
is more recent, being of a reddish colour while the lower
areas are paler; from the surface a large quantity of
bloody serum flowed. Hardly anywhere was the cut surface
dry, and only in places were the air cells distinctly recog-
be occupied by little plugs of lymph. The extreme apex
of this lung is occupied by a mass of firm, much pigment-
ed fibroid tissue in which may be seen the remains of
one or two cavities and several small cretaceous masses

a firm cheesy nodule about the size of a large marble & dense encapsuled, was found in the upper part of lower lobe Left Lung — Apex and posterior parts adherent.

Small extravasations in there, some of which were recent. A dense mass of fibroid tissue, similar to that in the other lung occupied the apex, & tending for 3" by 1½" in depth, unpigmented, interspersed with small calcareous masses and traversed by a small irregular cavity, the size of an almond. In the neighbourhood of this mass, towards the posterior part of the apex are several small grey granulations, which in one place are aggregated together. Another firm fibroid mass, the size of a marble exists towards the centre of this lobe. The inferior part of the lobe is passing into a condition of pneumonic consolidation, the cut surface being of a greyish red colour, bathed with bloody serum, & traversed portions sink. The lower lobe is moderately congested, & presents one small area of consolidation, situated centrally, and about the size of a walnut. Bronchial glands successively pigmented, with the exception of one small encreation, the size of a pea, they appeared healthy.

Spleen

Weight 3 VIss. Surface mottled, due to ecchymoses & intense congestion in patches beneath the capsule. Pulp tolerably firm, of a dirty chocolate brown colour, & scattered over with small extravasations. Malpigh. corpuscles not evident. Veins full.

Kidneys

Left 3 V. Capsule removed with tolerable ease, surface marked with small whitish elevations, the bases of which are hyperæmic. Cortex in section much diminished, pale, surface looks fatty. Pyramids darker in colour, and marked with

tubules choked by urinary salts. Numerous cysts, ranging in size from a pea to a marble are evident in the surface Right. ℥ v. presents the same features, the cysts however are not so numerous, nor does the surface appear so granular a small pale firm nodules about ½ the size of a split pea found in one of the pyramids. Bladder. ℥ vi. unne. walls & M. M. healthy

Liver

Weight 4lbs 4 oz. firm and on removal of the capsule the surface is slightly granular. A moderately deep groove extends across the right lobe in the ant. post. direction, bottom smooth not cicatricial. Close to the long. ligament in the right lobe is a superficial puckering of the capsule, which on section is seen to extend about ¼" & is composed of fibrous tissue & dilated gall-ducts. Hepatic veins contain some blood. Lobules though of a reddish colour are not injected. G. Stad. much dilated. 26 small gall stones size of Cayenne pepper. irregular. no pedicle. on pressure all the fluid from punctate biliary

Stomach

Rugæ present. Mucous membrane scattered over with small ecchymosis, & the capillaries are injected. Veins also full

Intestines – small & large – appear perfectly healthy

Brain

Dura mater not adherent (Skull unusually flattened at posteriorly) small clots in long. sinus. Pacch. granul. numerous in post Convolutions somewhat wasted, sulci deep & arachnoid over them granular & cloudy. Veins of pia mater moderately full. Brain substance firm, Ventricles contain full amount of fluid. Septum firm. Small gritty particles in corp-quadrig. Nothing abnormal in ganglia at the base. Arteries of Willis rigid but not remarkably so

Case XXXVI Acute Tuberculosis. Aortic Aneurism

– B. at. . Body that of a well built muscular man, large frame, well-knit. Rigor mortis present. Slight P.M. lividity in dependent parts. Pan. adipos. moderately developed muscles of a healthy red appearance
Abdominal organs in natural position. Intestines pale. No fluid in peritoneal sac. Diaphragm corresponded to 5th rib
Lungs in normal position.
Heart & Pericardium. No fluid to speak of in the sac. Both layers clear & translucent. A large patch of attrition over right ventricle heart. Full & right chambers distended. & on opening them large decolorized clots, with other contents were removed. Valves healthy. Tricuspid orifice of normal size. Left Vent. walls appear somewhat thickened. ant. mortem clot present. Mitral and semilunar valves quite healthy. about 1" from the latter valves several calcareous plates were noticed in the aorta which led to the inspection of the rest of the vessel & discovery of a large aneurism (unsuspected during life) arising from the posterior part of the aorta just beyond the arch, immediately below the left subclavian. The posterior wall of the sac was formed by the 3rd, 4th & 5th, dorsal vertebra, which were bare the intervertebral cartilages being much eroded.

Lungs. Right. a few old adhesions at the apex. the rest of the lung free. No fluid in pleura sac. Parietal layer healthy. visceral layer presented numerous scattered miliary granulations over the whole surface. On section of the lung from apex down the whole organ was found stuffed with tubercle, occurring in the form of greyish white small nodules, ranging in size from a millet seed to a hazel nut. No one portion of the organ seemed more affected than the other, & at no spot could a threepence be placed over normal lung tissue. At the apex was a small irregular cavity, the size of a horse-bean and near it a caseous mass, the size of a marble. No other evidence of old standing disease met with. Organ congested posteriorly. Bronchial air cells in ant. border appear large & dilated.

Left. Lung. adhesions from at apex. and posterior part above. On section presented the same appearance as the other. everywhere stuffed with tubercle. At the apex were two caseous knots, & a puckered fibroid cicatrix. The individual tubercles were firm, nowhere breaking down, often arranged in clusters. The bronchial mucous membrane was injected & from some of the smaller tubes purulent matter could be squeezed. Bronchial glands large. on section tumified. moderately pigmented and contained a few tubercles; in one there were two or three small concretions.

Kidneys. ℥ VI. each. Capsules detached readily. Surfaces show a number of small white bodies, half the size of a split pea. On section cortex & medulla equally injected. and scattered over with the small tubercles. Do - do being evident in each organ.

Spleen. ℥ IX ℈. Tolerably firm. A few miliary granulations evident on the surface & section. Pulp of dark colour. Corpuscles not distinguishable from the uniform injection of the organ.

Liver, lbs 4. 8. oz. firm. natural looking. On section. hepatic veins contained a considerable amount of blood. Lobules very distinct; centrat veins in many pill. No tubercle in substance or on the capsule. Gall bladder contained about an ounce of thin bile. D. can chol. patent

Stomach. contained a small quantity of dirty fluid. Mucous membrane soft easily torn, rugæ present, Large veins pill capillaries in many spots injected.

Intestines. No traces of miliary granulations on the visceral or parietal layer of the peritoneum. Mucous membrane pale throughout, injected only at one place about 16" from the pylorus. In the ileum were two small ulcers, one the size of a sixpence, the other of a threepence, circularly tuberculous, base made up of white nodules. peritneal surface dark injected & about one or two tubercles.
Large intestines healthy.

Brain. Dura mater non-adherent. Long. sinus contains a small clot. Sub arachnoid fluid in excess. elevating the visceral layer from the pia this place over the sulci very full No exudation or tubercle about the base. One or two noticed on branches of the sylvian arteries (?). On section. substance tolerably firm Puncta vasculosa marked. Fornix septum not affected. Lateral ventricles appeared somewhat larger than normal but the walls were of normal consistence. Parts about the bottom of the 3rd ventricle appeared soft. the commissure tore easily Choroid plexuses cystic. & about each was a large cyst size of a marble filled with whitish flocculent matter. Nothing noticable in careful section of the ganglia & cerebellum

Case XXXVII Stone in the Bladder

10 hrs PM

Æt. 66. 5=6 attempts at crushing.

Body that of a fairly built well nourished old man. Rigor mortis present Abdominal organs only examined. Omentum covered over the intestines completely & was somewhat injected Kidneys & bladder removed together.

Rt. Kidney. Organ very large. capsule & fat abundant On section, a quantity of dirty purulent matter escaped from the pelvis which was greatly distended & the walls in a state of acute inflammation, being of a livid red colour and presenting here & there patches of firmly adherent lymph. No calculi. The cortex and pyramidal portion were much swollen, the vessels full, & the whole appearance corresponded to that condition of acute Nephritis. There were no purulent foci, or lines of pus in the collecting tubules

Left kidney, large; pelvis also dilated but not so much as in the other, nor were its walls so acutely inflamed, the patches of lymph were absent. Parenchyma in same condition. There was a very large amount of fat about the pelvis of both organs, projecting up between the calyces

Bladder, contained about 3 ii of dirty purulent matter & the crushed remains of a large stone, weight. . another small one. the size of a bean, also present, & had a slight chip taken off. Walls of the organ thick. Mucous membr. intensely inflamed Prostate large. middle lobe projected much.

Liver. Spleen and intestines appeared quite healthy

28/10/76

Phthisis Case No 38. Fibroid Lung.

Body that of a medium sized woman. Rigor mortis almost gone. Skin of the upper portion of body, especially about neck of livid colour. + scattered over it minute ecchimatic spots.
Post mortem decomposition evident in dependant parts of body
Linea albicantes present in lower abdominal region + antero lateral region of thighs. Legs. + lower half of trunk edematous. Body not much emaciated. Face does not present characteristic emaciation of Phthisis.
Thorax + abdomen opened.
about 4oz of dirty yellowish fluid removed from peritoneal cavity. Situation of abdom organs normal. Stomach distended by gas
On opening the Thorax Heart & lungs pushed over to the right. Lungs found lying to right of median line. Base of heart + great vessels lie beyond costal cartilages of Right side.
In Removal of Heart 20 oz of blood escaped into pericardium, from no definite clot.

Right Lung; universally adherent & removed with great difficulty. Organ firm, solid & to the touch gives no indication of crepitation. On section no trace of the lobes of the lung remain. A large cavity occupies almost the entire apex, extending chiefly in the antero-lateral region, the posterior wall being composed of irregular fibroid masses, through which 2-3 large bronchi open directly into the cavity. The upper & antero-lateral walls are composed of a layer of fibrous tissue 1/4-1/2" in thickness, the outer part white, the inner portion darkly pigmented. Two irregular prolongations extend from this cavity downwards and forwards towards the anterior margin of the lung, Another long irregular cavity extends for 2" along the posterior part of the organ, immediately beneath the pleura, which is here thin. It is in connection with the cavity of the apex by two small openings. The lining membrane of these cavities ~~is~~ darkened in colour and traversed by numerous bands, the remnants of vessels & bronchi

The base of the organ is firmly united to the diaphragm, and the ~~portion~~ angle which is received into the angle between this membrane & the ribs is, for the extent of 1 1/2" transformed into a mass of white fibroid tissue, devoid of any traces of lung substance. Towards the anterior border this mass diminishes in thickness. Between the upper border of this and the cavity at the apex - a distance of 3" - the lung presents a marbled appearance, is dense, firm, & with the exception of one small spot, airless. A few small dilated bronchi are evident below, while immediately beneath the pleura are some small cavities filled with a bloody & purulent matter. The anterior border of the organ

is in the same condition, and in section numerous small cavities (some of which are dilated bronchi) with bloody contents are seen. The organ is not excessively pigmented
The main bronchus, and its branches of the 2nd & 3rd degree are moderately dilated. Bronchial glands pigmented, firm not enlarged.

Left Lung. adherent at the apex only. In section a large irregular cavity with thick dense walls occupied the upper and anterior part of the apex. Lining membrane haemorrhagic
Contents – about 3 ij. – pus mixed with blood
The remainder of this lung is extensively emphysematous especially at the anterior borders, but presented no other degenerative signs

Heart-

A large amount of blood flowed from the chambers of the right side, which were dilated and large. The walls of the right ventricle appeared a little in excess of normal thickness
Tricuspid orifice dilated, admitting four fingers as far as the first joint. segments slightly thickened at the edges
Musculi papillares look elongated & are pale at their apices. Pulmonary semi-lunar valves healthy
Left ventricle. Cavity and walls look of normal size
Mitral valves thickened. Aortic semilunar opaque & slightly atheromatous at their bases

Spleen

Of average size, tolerably firm. Capsule opaque Organ on section of dark purplish red colour, corpuscles of Malpighi indistinct. Vessels full

Kidneys . Capsules thick, and are detached with difficulty leaving the surface slightly granular. Substance from Cortex a little diminished. Vessels of the pyramids & the tubes full, One or two cysts noticed.

Stomach

Veins full, & dependent part of organ dark in colour. Mucus membrane softened easily torn.

Intestines

Beyond considerable injection of the veins nothing abnormal was observed

Uterus, ovaries & bladder look natural

Brain. Long clot in sup. sinus of dura mater Veins of Pia mater full in posterior parts. Nothing abnormal noticed about the superficial portions. Organ kept for dissection

Case XXXIX

Mary Fitzsimmons æt. 50 Autopsy 36 hours post mortem

General Appearance

Body that of a well nourished elderly woman. Rigor mortis still present in a slight degree. P.M. discolouration posteriorly. On inner surfaces of both legs there are extensive, dark coloured cicatrices. One in the left leg is covered with a few scales. Veins of lower limbs varicose. Skin of abd. greenish in colour. Linea albicantes present.

Pericardium

3 VIII of clear fluid. On the visceral layer are several ecchymoses. Small patch of fatty infiltration over the right ventricle. Beneath this patch the vessels of the sub-pericardial fat are injected.

Heart. Weight 20 oz. Right ventricle. Walls appear of normal thickness. Tricuspid and Pulmonary valves healthy.

Left Vent. Walls considerably hypertrophied. Nearly 1" in thickness over anterior wall. Muscle substance somewhat paler than natural. Mitral valves a little thick at free edges. Patches of atheroma at bases, especially that of ant. segment where it joins the semilunar. Aortic valves a little thickened. Ant segment presents several nodular calcareous masses on its inner surface where it is attached at the base. All the segments are more or less atheromatous at their attachments, and so is the aorta in the region of the coronary arteries. A few patches are present in the arch. Endocardium of left chamber cloudy especially on the septum. Musculi papillares opaque and dense at their apices, opacity in some extending to the substance

Lungs

Left. adherent by a few small bands. Organ crepitant throughout. Somewhat emphysematous slight puckering at the apex. On section the organ is dry no nodules. Right adherent to the chest wall and the diaphragm. Lobes also adherent to each other. On section the organ is dark, contains much blood, and from several cut bronchi tenacious purulent matter escapes. Posterior part - from to the touch, not much air in it, but still floats in water. Ant. margins emphysematous apex puckered

Spleen 12 3/4 oz. Superficial fissures run across its upper third. Capsule opaque. On section organ contains much blood. Surface of dark mulberry colour. Splen pulp scrapable.

Kidneys. Right 6 1/4 oz. Capsule readily removed Surface somewhat irregular. & several cysts are apparent On section organ of a uniform dark reddish colour Bases of pyramids slightly more congested. Cortex in places seems diminished. Small arteries at bases of pyramids very prominent. Left. 6 1/2 Capsule detaches readily. Surface & posterior border very irregular, especially at the lower part. In these irregularities numerous cysts may be seen. Not much wasting of cortex except in the spots corresponding to the irregularities Organ firm and denser than normal. Arteries at bases of pyramids look thick and are more prominent than usual

Liver 7 lbs. 6 oz. Organ firm to the

touch, capsule peels off easily. Anterior border of both lobes thin and atrophied. Gall-bladder projects below the margin & the liver substance above it is much wasted, the capsule fibrosed & the vessels dilated. On section the organ is uniform in colour, dark brown. Much blood exudes from the cut veins. On under surface of left lobe subcapsular vessels very apparent. In gall bladder are 7-8 soft stones, triangular in shape & of a black colour, a dozen or more flat pieces also present. Intestines

Nothing abnormal about the small intestine. Solitary glands, and individual elements of Peyers patches distinct. Large bowel healthy.

Brain 40½ oz. Considerable amount of blood escaped on the removal. Blood but no clots in the longitudinal sinus. Vessels of Pia mater moderately distended. Arachnoid over cerebrum opaque & slightly granular. On section brain substance offered considerable Puncta vasculosa well marked. Small amount of fluid in ventricles. Surface of rests over corpus striatum & thalamus corpus striatum & septum appear very soft & tear readily Nothing abnormal in third & fourth ventricle. On careful section no tumor & extravasation noticed in the substance

Case XL Phthisis

Body considerably emaciated, abdomen sunken, eyes remain open. Skin harsh and dry. Slight P. M. discolouration behind. Rigor mortis present.

Abdomen & Thorax

Position of abd. viscera natural. Omentum fatty. No fluid in peritoneum.
In the chest the pericardial fat appeared in excess.

Pericardium

3ii of fluid in the sac. On right vent. an erysipelatous patch of attrition, and immediately over it the posterior wall of the same chamber

Heart

Right auricle contains a partially decolourised clot & a good deal of blood fluid from the cava in excess. Rt. ventricle looks large. walls somewhat thicker than natural. Tricuspid orifice is dilated, admitting three fingers to the second joint easily. Valves - tricuspid and semilunar healthy.
Left ventricle, firm, rigor mortis present, & will appear very much thicker than natural. Mitral valves opaque & a little thickened & the semilunar are atheromatous at the bases. & are very dense, but competent. The segment penetrated. The arch of the aorta is considerably dilated and the intima covered over with patches of atheroma

Lungs

Right. Upper lobe presents a number of superficial puckerings, the largest of these exist at the posterior part of the apex. In their neighbourhood the lung

tissue is emphysematous, in one or two places dilated in bags fair the size of walnuts. The whole of the upper lobe and the ant. borders of middle and lower lobes also very emphysematous
On section two cavities are seen in upper lobe, one the size of a marble, filled with pus, the other, size of a walnut, ~~fille~~ empty, situated superficially. The walls are dark in colour, haemorrhagic in places, and two bronchi open directly into it. The largest of the pulmonary is immediately above the cavity & in its neighbourhood are the sacs of emphysema. Collections of miliary tubercles are present throughout the ~~lobe~~ & the middle lobe
The lower lobe is congested & contains very little air & no tubercles.
Left Lung, adherent, especially at the apex. Pleura over ant. part of lower lobe very dense, and fibrous. On section cavity, the size of a small apple at apex, and another the size of a walnut ~~exists~~ in the lower part of upper lobe. Throughout the both lobes numerous mass of tubercle were scattered which here & there were breaking down & forming small cavities.
Bronchial glands enlarged, dark, & caseous masses within.

Spleen

115 grms, small dark red in colour. Capsule tense, on section organ firm. Corpuscles evident

Kidneys

Right. 120 grms. Capsule adherent - small portions of the organ tearing away with it. On section the cortex is pale, and considerably wasted. Pyramids dark in colour

and in one a small pale body – a tubercle – exists
Left. 140 grms. corresponds to the other. Both organs are
firm, fibrid & contain a good many cysts in the cortex
Stomach

Small, empty & contracted, rugæ present
Mucous membrane thin and easily torn, Veins
in dependent parts full
Duodenum and Jejunum present nothing worthy
of note In the upper part of the ileum are some
small irregular ulcers with raised walls and thickened
bases, Many of these appear to have healed, leaving el-
vated transverse lines, which are evident by their pigmen-
tation. Solitary glands are enlarged, some of them looking
like peas beneath the mucous membrane, & on puncture
a white creamy fluid flowed out. Peyers patches are
indistinct. Termineum over small ulcers is unaffected
Liver

weight 1608. Upper surface presents a groove in the
posterior part about half an inch in depth. Six or seven
superficial puckerings exist over the surface of the right
lobe. A large irregular one and two or three smaller ones
are seen on upper surface of left lobe & on the under
surface of same is an irregular groove, running in the
antero-post. direction, the bottom of which is fibroid
On section the lobules are distinct central parts dark
blood exudes from the cut hepatic veins. Capsule
thin, slightly adherent. surface of organ a little granu-
lar. Consistence increased. Organ does not appear
fatty. Brain. Healthy as far as superficial examination extends
Arteries of body. atheromatous.

Case XLI. Epithelioma cerv. uteri. Pyometra
- C.S. - aged 80.

Body extremely emaciated.
Skin harsh dry & much wrinkled. Panniculus adiposus. Muscles wasted. Costal cartilages ossified
Position of abdominal organs normal, but in drawing up the small intestines from the pelvis a round tumour is seen between the bladder & rectum
Pericardium contains a small amount of fluid
Heart weight 320 grms, very soft & flabby
Very small amount of blood in the right chambers
Anterior segment of tricuspid valves thickened at the margin. Left ventricle appears thickened slightly, endocardium very opaque. Mitral valves dense & thick at margin alternators at bases Aortic semilunar, opaque slightly calcareous at convex borders. Aorta extensively coloured dull & its intima is studded over with alternate patches
Lungs. Left extensively adherent, & densely pigmented pleura covered with a thick dense layer, apex much puckered. Organ emphysematous at apex & ant. border otherwise unaltered. Right; apex puckered and adherent Pulmonary veins appear very large & distinct, remarkably convex to within 1" of the pleural surface.
Both lungs are dark in colour & congested hypostatically (hypostatic)
Spleen
weight 210 grms. Capsule covered over with a number of grm white almost cartilaginous, masses. Pulp extremely soft & dark plum colour

Kidneys. Left, weight 100 grms, small, capsule removed also leaves the substance with it. Numerous cysts through out the organ Cortex much wasted. Organ firm fibroid, & the small arteries at the bases of the pyramids are unusually distinct. Cortex pale, pyramids injected
Right kidney presents similar appearances
Bladder contained a small amount of urine
mucous membrane soft
Stomach. Small, walls both thick & mucous membrane is firm
Intestines. Duodenum & Jejunum ~~both~~ are normal
small follicular ulcers are present in the ileum and
caecum. Colon and rectum unaffected
Liver.

Very irregular in shape. From the left lobe passing forwards is a flat projection of liver substance about the size of the hand, attached by a broad base, which both above and below is separated from this lobe by slight grooves, not distinct in print. ~~Above~~ superficially this supplementary lobe is fibroid, and also is the left. Substance of right lobe above the gall-bladder much atrophied. Organ firm on section, capillaries of portal system injected.

Uterus & vagina

On removal of the viscera & intestines an oval tumor was seen occupying the pelvic cavity, & reaching to the brim & situated between the bladder & rectum in the position of the uterus. It was soft, distinctly fluctuating, and on examination proved to be a greatly distended uterus

On attempting to make out its exact position with reference to the rectum and vagina the finger was accidentally thrust into the lower part of the tumor (the walls in this situation being very soft) and a large quantity of laudable pus escaped. The Uterus rectum, bladder & vagina were all removed together when it was found that the cervix, uteri and upper part of the vagina were involved in a cancerous mass which occupies the whole circumference of the former & the upper third of the latter, not extended to either rectum or bladder. No trace of the canal of the cervix remains, an irregular portion, somewhat pedunculated, corresponds to the position of the os & lemnus The disease is confined almost entirely to the cervical portion of the Uterus, & tending only to a slight extent round the lower part causing a thickening of the walls in this situation The cavity of the organ is dilated into a sac, the size of a cocoa nut, & contains nearly a pint of pus. The walls are thin, nearly 3 lines in diameter, and lined by a definite pyogenic membrane. Ovaries small, & contracted. Round ligaments & Fallopian tubes inserted about the junction of the lower & middle thirds of the dilated body. One of The latter could be traced & opened as far as the walls of the uterus itself when the canal was lost; There was no dilatation of their internal orifices ~~the same~~

The cancer was soft & white in colour, in the vagina & lower part of cervix, firmer above where it gradually merged into the uterine walls. In histological characters it corresponded with the epithelioma of this situation, though the number of large irregular cells with bold nuclei surrounded one of encephaloid. There were no "nests" There were several large cells containing other smaller ones, as though formed endogenously (or by vacuolation), and some "giant" cells

Case XLII Morbus Brightii

Tetanus at.

Body that of a medium aged man. Great emaciation, Rigor mortis present. P.M decomposition behind

Bedsores, small ones, on back

Pericardium contains about a drachm of clear fluid. Considerable amount of sub-pericardial fat.

Heart. weight 12 4 oz. Dark clots escape from right chambers on removal. Rt. auricle normal. Rt vent. ant. portion clot entangled in col. carnae. Walls of natural thickness Tricuspid valves a little thickened at the margins. An elevated patch of endocardial, of a yellowish colour, ½" in length & ⅛ in breadth exists in the post wall of coronary arteries. Pulmonary semilunar healthy, one segment fenestrated. Left ventricle. Walls hypertrophied 3/4" & an inch in thickness. Cavity a little dilated. Mitral valve. opaque posterior segment thick. Aortic semilunar. dense opaque & atheromatous at bases. but still competent. Aorta, large. Atheromatous near the valves. No disease in the thoracic and abd. portion

Lungs, collapsed & lightly when the chest was opened. Right. adherent behind. Upper lobe, and anterior part of lower lobe emphysematous. Posterior lower lobe plum colour & firmly, heavy, on section, dark & surface bathed with blood and serum. Pieces of this pneumonic process involves the whole of the lower lobe with the exception of the ant border. Left lung, adherent at apex & laterally to a slight extent. Very emphysematous also

A small area at base is firm, the section bathed with much blood and serum.

Spleen. weight 148 grms. small. capsule shrivelled, On section trabeculæ and vessels very evident

Kidneys

Left. 98 grms. Capsule detaches readily, surface of organ smooth. Vena stellata very evident. On section cortex pale, malpighian bodies indistinct, alternating lines of congested vessels and pale tubules run from pyramids to the surface. Organ firm to the touch. A good deal of fat about the pelvis. Right. 98 grm. Presents similar appearances

Stomach

Mucous membrane of a grey colour, easily torn. Large veins full. Vessels about Pylorus seem unusually full.

Intestines. Duodenum and jejunum appear healthy. Ileum, veins, large & small, injected. No changes in Mucous Membrane

Liver

1130 grms. Organ small, firm to the touch. On section much blood exudes from the hepatic veins. Central veins of lobules. full. producing a slight degree of nutmeg liver

Brain

Tolerably firm. Vessels of Pia mater full. On section consistence of white substance good. Puncta vasculosa very evident in posterior part. Septum & fornix easily torn. No trace of any old & transient (the lad suffered from Hemiplegia. Arteries stiff but not calcareous

Case XLIII. Tubercular Meningitis.

Elizabeth Hoy. ætat 4.

General appearance Body that of a tolerably well nourished girl. Rigor mortis present in a slight degree. Post-mortem discolouration in dependent parts. Thin layer of Panniculus adiposus. Muscles normal in colour.

Brain. weight 1270 grms. Parts about the optic nerves matted together, arachnoid thickened. Pia mater unusually adherent. No lymph or inflammatory products either at the base or on the sylvian fissures. No miliary tubercles to be discovered on superficial inspection, but on removal of the middle cerebral arteries & washing in water numerous granulations were found, chiefly as prolongations of the small arterioles passing into the convolutions. Veins on the cortex moderately full, convolutions only a little flattened, the small vessels upon them injected. On section white substance pale, puncta vascularosa indistinct. Lateral ventricles distended and an ounce of serous fluid. Lining membrane distinctly granular. Surfaces of ganglia soft. Fornix & septum lucidum exceedingly soft. & torn in the removal

Spinal Cord

Much blood oozed from the vessels about the dura mater, and in the middle dorsal region a thick layer of fat exists between this membrane and the lamina.

Arachnoid - visceral leaf - looks opaque in cervical region No tubercles in parietal layer. In the lower three fifths the visceral layer was covered with numerous small cartilaginous

plates, thin, flexible, irregular in outline, and presenting the usual glistening appearance of these bodies
No trace of miliary tubercle in the pia mater. Substance appears normal, though soft.

Thorax and Abdomen

Position of abdominal viscera normal. Sigmoid flexure very long, and passes across from left to right just above the pubis; rectum descends on the right side.

Pericardium distended, & contains ℥vi of turbid fluid a small amount of which covers it externally

Heart - weight 300 gms.

No clots, but considerable quantity of blood in the right chambers. Valves of the right side healthy. Walls of left ventricle look a little thick. Valves healthy. Endocardium on septum, immediately below the aortic valves opaque.

Right Lung. A large amount of blood flowed from the pulmonary veins on removal. Whole of the lower lobe dark in colour, heavy, on section, surface both with much blood and serum. Portions from the superficial region of this lobe float, irregular from the deeper parts they sink. No crepitation can be felt. Deeper part of the middle lobe of the lung in a similar condition, and also the anterior part of the upper lobe below. A few miliary tubercles are seen on the pleura of this lung and throughout the substance

Left Lung. A few tubercles in the pleura & in the substance. The organ is crepitant throughout, and

contains an average amount of blood
Bronchial glands enlarged, one presents several caseous masses. Small miliary tubercles abundant in them

Spleen.

Capsule slightly opaque and covered with a few small fibroid thickenings. A small supernumerary spleen, about the size of a walnut is present just below the tail of the pancreas, Anterior border of organ presents three fissures, Posterior border two. No tubercles on capsule or on substance. Pulp soft & dark in colour

Right Kidney.

130 grms Capsule easily detached, surface smooth & venae stellulae evident. On section two small tubercles noticed in the cortical portion. Cortex presents an alternating series of red & white lines. Pyramids slightly congested & a good deal of blood oozes from the vessels at their base.

Left Kidney

160 grms. appearances similar to those in the right. No tubercles

Stomach. Post mortem softening in dependent parts. Small amount of mucus coats the surface

Duodenum. Healthy. Bile flows from the papilla into pressing the gall bladder.

Ileum. Peyers glands, solitary and agminated very distinct

Liver. 1235 grammes. Firm on section of a uniform reddish colour. Lob. indistinct. Blood flows present. Hepatic veins

Uterus & Ovaries. A recent corpus luteum, about the size of a marble in right ovary. It presents a yellow border enclosing a darkened clot. M. M. of uterus pale. Epithelium glands present & appear normal

Case XLIV Heart disease. Pleurisy. Pul. apoplexy

James Watt. aged 39. P.M. 30 hours after death

General appearance.

Body that of a large powerfully built man. Skin of the trunk of an icterod hue. Upper part of thorax and neck intensely livid. Face swollen skin suffused; bloody fluid oozes from the mouth. On palpation the skin beneath the sternum and back part of the trunk emphysematous, especially marked about the root of the neck. Legs & lower half of the thighs adematous. Scrotum swollen and contains fluid. Posterior aspects of the body of a dark red colour

Thorax and Abdimen.

Intestines appear of a dark brown colour. Viscera of viscera normal. Stomach & intestines distended with gas. 3iii of fluid in peritoneum Left pleural sac contains 96 ozs of serum slightly tinged with blood. no flocculi. Right pleura contains 3iii of fluid Left lung slightly adherent behind. Right lung free.

Pericardium

3ii ℥ of turbid straw coloured fluid. Patch of attrition over right ventricle. Subpericardial fat abundant and tinged lightly with bile

Heart- a large quantity of blood escaped from the vessels on its removal. Organ appears large. weight 610 grms 14½ ozs Right auricle much dilated with blood and grumous clots. Endocardium deeply stained

Right ventricle contains dark clots; walls stained Tricuspid orifice dilated measuring 5 7/8 inches in

in circumference, and admitting the four fingers nearly as far as the second joints. Valves healthy. Walls don't look thicker than natural 1/4" or even less. Pulmonary valves normal and competent. Circumference of the orifice 3 inches.
Left ventricle. Small & partially decolorized clot in the mitral orifice & adherent to the chordæ tendineæ. Chamber appears much dilated, measuring 4 1/2" from apex to aortic ring, and bulges much towards the right ventricle. Endocardium thickened, opaque, not much stained, Walls, over middle of anterior part 7/8" in thickness. posterior wall 1/2" Ventricular septum one quarter of an inch below the aortic valve 1/2" in thickness.
Mitral valves slightly thickened at the edges, orifice measures 4 1/4 inches in circumference. Valves competent. A small calcareous mass at the attached border of the anterior segment near the aortic valve
Aortic semilunar valves. Segments thin, quite healthy & competent. Circumference 2 3/4 inches at the ring. Diameter of aorta 1" above the valves.
The aorta looks small, & the segments of its valves look smaller than those of the pulmonary artery
Columnæ carneæ firm, some fibroid, a few of the thinner ones calcareous
Substance of left vent, & whole heart, looks pale, and on examination is found in a condition of advanced fatty degeneration. A good deal of fatty infiltration also exists between the individual fibres
The aorta in its course is not atheromatous. Intima healthy Smaller arteries also are not diseased

Lungs

Left. dark in colour & ternally. Pleura covered over with shreds of lymph. Apex and posterm parts of the organ in a condition of collapse, and only slightly crepitant. Anterior portion of upper lobe the seat of two large apoplexies. The larger one is situated in the lappet over the heart, is 2" in length and extends through the whole thickness. The other, situated above & anteriorly is about the size of a walnut, and is surrounded by a pale condensed wall. The lung tissue about these extravasations is pervious and in a condition of Pneumonia. Another extravasation occupies the anterior border of the lower lobe ~~behind~~ below & the lung tissue about it is consolidated.

Right lung. crepitant throughout, congested posteriorly a small consolidated area — lobular Pneumonia — at lower part of anterior lobe in front. Otherwise looks healthy

Spleen

250 grammes. Two fissures in the ant. border. Organ tolerably firm, much blood & nodes. Malpighian bodies indistinct. Pulp of usual colour.

Kidneys

Right. 180 grms. Capsule readily detached On section much blood exudes. Cortex pale. Malpighian tufts alone injected. Pyramids red in colour.

Left. 175 grms. Presents two puckerings in the upper part of the organ, & these extend for a short distance into the substance & examination tubules of cortex blocked up with epithelial debris, & contains a good deal of fat, & granules in cells

Stomach and Intestines present nothing abnormal, the larger veins being as a rule full. The former contained about one pint of dirty fluid M. M. soft-

Liver

1600 grammes. Surface smooth. Organ of good consistence. On section the large veins full. Lobules tolerably distinct and present a very beautiful nutmeg appearance.

Gall bladder contains a small amount of bile.

Brain. Veins of Pia mater full. Arachnoid a little opaque over the sulci. Nothing unusual about the base. Arteries are not diseased. Substance not examined as organ was kept for dissection

Case XLV Cancer of Tongue

James Learmouth at 36

Body that of a slender man, thin, weak musculature
Abdomen greenish. Post-mortem staining posteriorly
Neck swollen in anterior and lateral regions. A tolerably
recent incision extends through the skin of the lower lip
and chin. Thorax long and narrow
Thorax and Abdomen.

Viscera pushed down. Liver 2"
below the margin of the rib in the mammary line
Transverse colon passes across just above the pubis
Diaphragm corresponds to the 5th rib
On opening the thorax the left lung extends over the heart
and is attached to the pericardium. Tumes beneath
the manubrium sterni infiltrated with pus

Pericardium

Contains a small amount of clear amber
colored fluid.

Heart. Rt much blood escaped from the veins on its
removal. Right ventricle contains two large colorless
~~clots~~ polypi, firm & closely adherent to the walls, & extend
into the pulmonary artery and through the tricuspid
orifice. Edges of tricuspid valves a little thick
Pulmonary semilunar valves normal.
Left ventricle contains small colorless clot. Mitral valves and
orifice normal. Aortic semilunar healthy, anterior
segment fenestrated. Arch of aorta a little athe-
romatous. Muscle substance firm and of good
colour



Lungs. Left, adherent at the apex and base. Organ crepitant throughout. Slight puckering at apex. Pleura & tissue of lung considerably pigmented.

Right, strongly adherent laterally & at apex & base. ~~The section~~ Crepitant at anterior border & base; middle lobe and lower part of upper prim, & the surface on section is bathed with sero-sanguineous fluid. A small purulent focus at central part of middle lobe, not a definite collection of pus but an area of the lung 1" by 3/4" irregularly infiltrated

Spleen, 108 grammes. Substance soft, & contains a good deal of blood

Kidneys.

Left, 120 grms; capsule readily detached. On section colour uniform, substance firm & healthy

Right, 115 grms, presents similar appearances

Stomach, contains much dark fluid. Vessels congested in dependent parts.

Intestines. Large veins full; mucous membrane looks healthy. A small invagination exists in the ileum.

Liver 1580 grammes. Organ long and narrow, substance firm. Lobules indistinct. Large vessels full. Superficial part of left lobe pale and looks fatty.

Gall-bladder contains a thick tenacious bile

Brain 1487 grms. A good deal of blood and serum escaped in the removal. Arachnoid opaque, granular & serous infiltration exists beneath it

Substance of the brain presents nothing abnormal.

The lungs of the pock are infiltrated with pus in both side & in front: There was no definite collection, but all the interstitial connective tissues

Beatrice M. 7

Case XLVI

Flora MacDonnell

General appearance. Body that of a moderately well nourished short woman. Rigor mortis present in a slight degree. P.M. discolouration in posterior parts. Skin of face of a slightly yellowish hue. A small abscess with distinct fluctuation in upper third of left thigh, and another one exists - which had burst - in the opposite thigh. Thorax & Abdomen

3L of fluid - turbid & amber-coloured - in peritineal cavity. Stomach much distended with gas. A considerable amount of pericardial fat. No fluid in pericardium

Heart-

Patch of attrition over right ventricle. Large clot-ourlers clot in right vent. Tricuspid orifice large. Valves healthy, one of them penetrated. ~~Aort~~ Pulmonary semi-lunar healthy, one segment penetrated

Left ventricle, contains no clots. Mitral valves a little thickened at edges, Chordæ tendineæ also firm & thick Small patches of atheroma on the valves. Aortic valves a little thick and opaque, Middle one penetrated.

Muscle substance flabby & pale.

Lungs. Left. No adhesions, slight puckering of apex organ crepitant throughout. On surface section bathed with serous fluid. Right. Cicatrices at apices. No adhesions. Much serum exudes from the section. Posterior parts of both lungs in a condition of collapse

Spleen appears normal

195 grms.
Left. Kidney. organ, soft, capsule opaque, & brings small portions of the substance with it. venæ stellatæ well marked, moderately amount of blood in the organ One cyst in pyramid
<u>Right</u>: 180 grms. is more granular, & contains 1/2 a doz cysts.
<u>Stomach</u>, contains a quantity of dirty dark fluid, dependent part dark in colour. M. memb. soft.
Duodenum. healthy. jejunum normal. Mucous membrane of ileum thickened. Peyers patches not distinct. Large bowel. normal.
<u>Liver</u> 2535 grms. slightly granular on surface. whole organ of a pale yellowish colour, on section quite bloodless, interlobular spaces yellow. & distinct. On examination substance found in a condition of advanced fatty degeneration
<u>Uterus</u>.

Ovaries extremely cicatricial. Nothing unusual about the walls or m. membrane of the uterus.

<u>Brain</u>

Surface of organ pale, only a small amount of blood in vessels. Organ kept for dissection. Nothing abnormal about the base

Case XLVII Albuminuria. Pregnancy. Peritonitis.

General appearance. Body that of a medium sized woman. Rigor mortis has not come on. Face swollen and a dirty yellowish fluid oozes from the mouth. Pupils of moderate size. On pressing the breasts a milky fluid flows from the nipples. Abdomen enormously distended the skin over the hypogastric regions thickly set with linea albicantes. Thighs and legs oedematous - the right more than the left, both of alabaster whiteness -

Thorax and Abdomen.

Twenty pints of opaque somewhat milky serum with flocculi of lymph, were removed from the peritoneal cavity. Both visceral and parietal layers of this membrane of a bright rosy color, due to the intense injection of the finer vessels. Thin flakes of lymph covered over the coils of the intestines, in many places matting them together. The liver was closely united to the stomach, by a tolerably thick layer of greyish white lymph. The pelvic peritoneum also involved, the ovaries are dark in color and coated with Exudation. The stomach and intestines are much distended, their coats infiltrated and easily torn. No Effusion into the pleural sac or in pericardium

Heart.

Right chambers gorged with blood and on removal over 30 oz escaped from the cut vessels into the pleural cavities and there speedily coagulated. Right ventricle - no antemortem clots. Tricuspid and pulmonary semilunar valves healthy. Left ventricle firmly contracted and hard to the touch. Cavity small, no clots. - Anterior segment of mitral valves thicker at the free margin than the posterior and the endocardium upon it is opaque & near its base atheromatous. Aortic valves competent, segments thin corpora arantii distinct. Nothing abnormal noticed in the auricles.

Lungs

Right adherent posteriorly and at the apex by a few bridles. Organ crepitant except at the base and hinder part of lower lobe which is very dark in colour and almost airless and contains a large amount of blood. A few scattered patches dark deeply congested exist in the middle lobe - Left. Upper lobe with the exception of the extreme apex in a state of engorgement the section bathed with much blood and the tissue almost airless. Posterior parts also much congested and b - & small appoplexies are present.

the anterior portion of the lower lobe alone presents a natural appearance
A few slight adhesions also on this side

Spleen.

Tumors, firm, dark in color. A fissure exists at the anterior border A fresh hemorrhagic infarction present in this situation, irregularly wedge shaped color reddish yellow with a zone of hyperaemia about it. -

Left Kidney. Capsule easily torn from the surface (except at one spot) and thin. Organ soft, rounded & swollen. The surface of the cortex is smooth, the vena stellatæ small but uniformly filled. On section not much blood exudes. The cortex is pale opaque and mottled, the Malpighian tufts are distinct but only here and there are the loops of vessels passing down the cortex full. The pyramids are of an uniform dark red colour.

Right. Presents the same appearances The pelves of both are injected. and about them is a moderate amount of fat.

Bladder

Contains hardly 3 i. of turbid fluid. Mucous membrane healthy

- the smaller vessels injected in places

Stomach.

Much distended with gas and contains about ½ a pint of dirty yellowish fluid Mucous membrane looks natural. —

Intestines.

Beyond the swelling and the infiltration of the coats there is nothing special to be observed. A single ascaris found in the duodenum

Liver.

Consistence good. On section lobules distinct and much fluid flows from both large and small vessels

Brain. by request not examined. —

Case XLVIII Phthisis. Hamoptysis.

General appearance

Body that of a small moderately developed man. Rigor Mortis present in a very slight degree. Blood ~~flowed~~ about the mouth and nose. Skin white. Veins show clearly through it

Thorax and Abdomen

Stomach distended & extends into the left hypogastric region Omentum contains a few small amount of fat In the thorax Lungs do not collapse meet in the Anterior Mediastinum. Right Lung middle lobe covers over the right Auricle & the greater portion of right Ventricle. On the surface of middle lobe are six or eight dark areas. Right Lung presents a few adhesions laterally and behind. Left Lung almost universally adherent

Pericardium

No fluid in the pericardial sac Heart On removal a large quantity of blood escapes from the venous orifices Right Auricle Natural Right Ventricle contains one or two small clots and considerable quantity of fluid blood Tricuspid & Pulmonary Semilunar valves healthy

Left Ventricle. Contains no clots. Walls of normal thickness. Endocardium a little opaque. Mitral Valves normal. Aortic Semilunar valves healthy. Three segments penetrated. Two of them on both sides of Corpora Arantii

Lungs.

Right: full in volume. Anterior margin & does not collapse when borders. Emphysematous. On Section a cavity the size of a large walnut exists in the lower & anterior part of the upper lobe. This Cavity is full of blood. That destroys walls and contains one or two small clots. The upper of this lobe is much infiltrated with serum and almost solid.

At its anterior border are several caseous masses and small cavities.

The Middle Lobe is Emphysematous. Contains patches of Congestion. It contains a large number of small miliary tubercles.

Lower Lobe. Emphysematous in front. Congested posteriorly. The Congestion is irregular, and on close inspection many of the apparently congested areas are found to be small bronchioles filled with clots & the lung tissue about stained. Some of the dark spots are not of this nature

A few Miliary tubercles also noticed in this lobe, And a small Cavity exists at its upper part. The Bronchi of this lung Contain Coagulae

Left Lung

Two large cavities-Size of walnut exist in the lower and lateral region of the upper lobe. Both contain blood & grumous clots. Remainder of this lung contains numerous caseous masses and a small cavity in the lower part of the anterior border. Posterior part of this lobe is solidified, airless, contains numerous tubercles and is traversed by a number of fibrous septa

Lower Lobe. At the upper and posterior part a cavity the size of a small apple exists with irregular walls and contains dark clots. Another cavity the size of a large marble exists a little anteriorly At the lower border of this lobe are two irregular patches of apoplexy Numerous miliary tubercles and larger tubercular nodules

Spleen

165 Grms. Organ soft. Pulp irregularly congested, and very friable. A few miliary tubercles in the substance - None on the capsule

Right Kidney

158 Grms. Capsule readily torn off leaving surface smooth. Pyramids marked

On Section — Cortex mottled. Malpighian corpuscles distinct

Left Kidney

170 grms. Capsule does not detach quite so readily. Substance contains a moderate amount of blood. Cortex presents a series of alternating light and dark red lines

Stomach

Distended with gas. Contains a quantity of dirty fluid matter

Mucous membrane pale except in dependent parts and covered over with a black tenacious matter

Intestines

Appear healthy. Peyers patches indistinct: Solitary glands not enlarged

No ulceration in the Caecum

Liver

1820 grms. Organ firm. Surface smooth. On section much blood flows from the large veins. Color, uniform. No tubercle or capsule or substance

Bladder

Contains a small amt of urine

Mucous membrane healthy

Bronchial glands enlarged & crumpled & contain numerous tubercles. They are not caseous

Brain.

A good deal of blood flows from the soft parts. Dura Mater not adherent. Longitudinal Sinus Empty. Arachnoid over the Sulci a little opaque & granular. Vessels of the Pia Mater full. No pus or product of Inflammation about the base. Substance of Brain firm. Grey Matter dark. Puncta Vasculosa well marked. Nothing abnormal noticed in the Ventricles. Lining Membrane of Lateral Ventricles a little granular. Nothing abnormal noticed about the Ganglia at the base or in the substance on section.

McEwen.

Case XLIX Aneurism. - Aorta.

Campbell

Rupture into Right pleura.

General appearance.

Body that of a well built muscular man, a little to the right of sternum about the middle, is an irregular oval projection on cutting the skin over the sternum, the sac of an aneurism was opened and dirty bloody fluid escaped. On removal of the sternum and cartilages of the ribs it was found that the under surfaces of the 3rd 4th & 5th sternal corresponding found much eroded, the 3rd cartilage having almost entirely disappeared, and the sternum opposite this point thin and honeycombed. The sac of the aneurism lies immediately beneath the sternum which, with the aforesaid cartilages forms its anterior wall. It extends somewhat to the right side, & is filled up with old laminated clots externally & dark fresh ones internally. The mass removed from the sac filled the two hands. The site of rupture was discovered at the upper right side of the sac close under the ribs at which point which point the blood had burst into the right pleura immediately at the base of the middle lobe of the lung by an opening somewhat larger than the half dollar, with irregular margins. The sac is in connection with the ascending part of the arch of the aorta, springing from the right side and communicating with it by a round orifice 1½" in diameter. The walls are thin, formed chiefly of condensed pleural and mediastinal tissues. The right pleural cavity is full of blood which has coagulated the serum floating uppermost. A large clot-

forming a mould of the cavity, & grooved by the ribs was removed entire, & weighed 3½ lbs. The lung on this side was entirely collapsed and airless being pushed back against the vertebral column. The surface of the visceral pleural was roughened, irregular, and covered over with minute patches of lymph. This was most evident on the middle lobe near the sac where an adhesive pleurisy had also been set up

Heart, pushed over to the right side, and placed more transversely than normal. A good deal of blood exists in the right chambers, the walls & valves of which are quite healthy. Left ventricle is firmly contracted, the walls thick, muscle substance of good colour. No clots. Endocardium opaque. Mitral valves a thickened slightly at their edges. Aortic semilunar, firm, thick, contracted a little at the free borders, the corpora arantii large. The central part of the segments are still translucent though opaque.

Aorta. On the right side of the ascending portion immediately external to the pericardium is the large round orifice of communication with the aneurismal sac, the margins of which are thick and project a little into the sac. The communicate which is given off immediately above the orifice is dilated admitting the first phalanx of the thumb. Patches of atheroma are scattered over the intima of the arch.

The Abdominal organs were not removed - as the body was retained for dissection. So far as external inspection went they appear healthy.

Case L Aortic valve Disease

Male, ab 43. Pub. N. Reports 1880 - p. 237.

Body that of an averaged sized man. Ecchymoses noticed upon arms anterior surfaces, and about the neck especially abundant behind. Legs swollen edematous, abdomen slightly protuberant. Skin of upper half of body lightly icteric. Thorax and abdomen. On opening the abd. the omentum appears of a dark red color the veins being very full. ℥ j of turbid fluid in the cavity. Positions of viscera normal. In the thorax the heart occupies a large space in the ant. mediastinum. Lungs adherent laterally by a few old bridles, & do not collapse much. Several spots of a dark color - apoplexy - noticed at the anterior margins.

Pericardium, no fluid in the cavity, a few small ecchymoses along the ant. auricular groove. Subpericardial fat in moderate amount.

Heart; weight with arch of aorta attached 23 oz's. Right auricle distended with dark semi-coagulated clots. Much blood escaped from the venae cavae. Chamber much dilated. Eustachian valve persists. Orifice of coronary vein very large, its valvular fold thin and penetrated. Foramina Thebesii large, 3-4 of them very evident. Annulus ovalis attenuations. Endocardium a little opaque. Musculi pectinati in the appendix in places separated from each other, the wall of the auricle between them being thin and translucent.

Right ventricle; cavity dilated and full of dark clots. Wall ant. part - near centre from 2/8 - 3/8" in thickness. Endocardium natural looking except at one one spot near the junction of the segments of the tricuspid and just below the semi-lunar valves. Tricuspid orifice 5 1/2 inches in circumference. Valves thin except just at the points of attachment of the chordæ tendineæ. Edges on the auricular surface present gelatinous thickenings. Orifice of pul. artery 3 1/2" in circum. Semi-lunar valves thin; one segment presents a small perforation near the margin. Pulmonary artery normal.

Left auricle appears a little larger than natural. Appendix narrow; not dilated. Endocardium very opaque.

Left Ventricle, contains a small quantity of dark blood. Chamber dilated. Length from aortic ring to apex 4 1/8". Endocardium over septum opaque, also along the edges & some of the columnæ carneæ & tips of the musculi papillares. Ant. wall at the middle one inch from the septum 7/8" in thickness. Mitral orifice 4 1/2" in circumference, valve somewhat thickened in the annular surface. Aortic orifice 3 5/8" in circumference at the ring. Aortic valves, incompetant. On slitting up the aorta two segments only are noted, one, the posterior situated above the ant. segm. mitral, is large occupies nearly half the circumference of the tube, measuring 1 1/2" along the straight margin 2" along the attached border. This segment is opaque, thickened in spots by atheroma. Sinus of Valsalva behind it large. The other segment is incomplete, a semicircular V shaped piece being absent from the ant end. The straight border extends for 7/8" & then terminates in a rounded ~~border~~ angle. The edge of this segment is round and thickened, and the whole valve opaque. A firm atheromatous band crosses the attached border at right angles. The aortic ~~cycle~~ of the segment presents and indistinct thick fimbria, about the middle of the attached margin, uniting it to a thick elevated atheromatous mass, which also serves to divide the sinus of Valsalva incompletely into two; the one behind the imperfect side being small, the other of fair size. There are three openings of coronary arteries seen above the imperfect valve, the third is small & has close to it another small opening about the size of a pins head

The Aorta itself is dilated and large; circumference one inch above the valve 4 3/8", at the junction of the ascending portion & arch 5"; at the commencement of descending portion 2 1/2. The whole intima is scattered over with round yellowish white masses of atheroma, which extend also into the thoracic portion.

On microscopical examination the heart-fibre was found moderately fatty, here & there plates presenting the dark yellow granules of brown atrophy

Lungs. R. 3vi of turbid fluid in the right pleural sac.

Right, presented three spots of apoplexy; one occupying the whole thickness of the free margin of the middle lobe, & tending two inches towards the root; another, smaller one, at the ant. free margin of the lower lobe; and a third the size of a walnut in the posterior part of the lobe. The remainder of the lung was crepitant, and superficially contained much blood. The branches of the pulmonary arteries appear much dilated. Left, presents two apoplectic spots; one in the free margin of the upper lobe, involving the whole of a little lappet (partially separated by a small fissure) over the heart; the other in the posterior free margin of the lower lobe. The rest of the organ was crepitant

Spleen, somewhat enlarged, firm; capsule opaque. On section the tissue is dense and of the usual colour. Large veins full. Malpighian corpuscles not evident

Kidneys, appeared about the normal size. Capsules do not detach very easily, and small bits of the organ remain attached. Surfaces a little granular, lobulated. On sections the organs firm, dense, cortex not marked. Vessels full, and a good deal of blood exudes from them

Liver, about the normal size. Surface a little granular. The capsule over ant. part of left lobe, and liver & gall-bladder thick. Organ on section firm; vessels of the hepatic system injected lobules dark red in the centre and pale or yellowish at the margins - nutmeg condition. Large veins full

Beyond a filling of the veins nothing abnormal noticed in the stomach or intestines. Brain not examined

Pleuro-Pneumonia

1/12/76

Case LI. Henry Empke age 36.

P.M. 25 Hours after death

General Appearance

Body that of a well built muscular man Rigor Mortis present. Signs of P.M. discoloration in the dependent parts & along the veins of the Extremities

Thorax & abdomen.

Omentum fatty. Liver extends about 3 inches below the Ribs in the Mammary line. Intestines Pale. No fluid in Peritoneum. On Removing the Sternum a thick layer of grayish yellow lymph lies over the Right Lung. 6 oz of turbid Bloody fluid in Right Pleural cavity

Right Lung uniformly hepatized. Nowhere crepitant. Extreme Base of Lung is in a condition of Collapse. On Section from apex to Base the organ presents all the characters of Pneumonia in the second stage

Cut Surfaces firm reddish in color. The little granular plugs filling up the air cells very evident. Only a very small amount of fluid exudes from the surface. The whole of the Pleura with the exception of the part about the Root of the Lung is covered over with a thick layer of recent lymph of a yellowish white color. In Places. this layer is fully 1/4 of an inch thick

(Weight of Right Lung. 3 lbs. 6½ oz. Left Lung. 1 lb. 13 oz.
difference ∴ = 25½ oz.)

The layer strips readily from the visceral Pleura, Parietal Layer of Pleura is every where injected & of a dark red color

Left Lung. Dark in color. On section surface bathed with a large amount of serous fluid At lower lobe behind there is a patch of Pneumonia irregular in form. Some spots isolated surrounded by intensely congested & oedematous Lung tissue

Anterior Portion of upper lobe anemic & in a condition of Collapse

Heart. 380 grammes

Right Chambers filled with dark solid Clots. In the auricle closely interwoven with the Musculi Pectinati.

Right Ventricle also contains firm partially decolorized Clots which extend through tricuspid orifice into the Pulmonary artery

Tricuspid Orifice & valves normal

Pulmonary semilunar valves normal also

Left Ventricle. Mitral valves Healthy

Aortic semilunar valves a little opaque

Anterior segment of Mitral valve a little atheromatous at the Base

Arch of aorta appears normal

Right Kidney 230 grms. Capsule detaches readily surface of organ slightly lobular. On section much Blood exudes from the vessels at the Bases of the Pyramids

Colon slightly swollen & bruised adherent
duodenal & right kidney
Left Kidney. Appearances similar to those of
the Right Kidney. Weight 220 grammes.
Spleen 248 grammes. Bruised 3 grammes in its ant.
Margin Organ texture soft flabby. and
Pulp. Bruised a Maroon color
Small Intestines. Nothing abnormal noticed
in Small Intestines
Nothing unusual noticed in Stomach &
Duodenum.
Large Intestine. Normal
Liver. 2980 grms. Surface smooth. On Section
Lobules not very distinct Large veins full
some of them contain clots. Large amount
of Blood exudes from them on section
Gall Bladder. Almost empty. Contains
Superior Mesenteric. contains dark grumous
blood & also in the Iliac & Femoral veins
Aorta contains small clots
Brain. Organ firm. Vessels of Pia Mater
tolerably full. Nothing abnormal noticed
on External Exam of Organ which was
reserved for dissection
Weight 1400 grammes

Case LII. 167

Cancer of Tongue – Secondary in Liver

Norris 1/12/96

General appearance of the body.

Body that of a
very old woman Emaciation Extreme
Skin of a dirty dark brown color
On opening the thorax Lungs collapse. Only
a few bridles of attach them to the chest
wall front. Both very adherent laterally
& behind. Infiltrated in Edematous
Right Lung Ant Portion Emphysematous
In upper lobe Anteriorly is a large solid
nodule made up of carcinomatous tissues
Intermingled with a very dark color
At the lower part of this lobe is another
precisely similar one & two distinct
cavities. Middle lobe free. At upper portion of
lower lobe is another collection of small car-
cinomatous tissue. & the tissue between them is
fibroid & infiltrated Pigmented
Left Lung. Apex on section almost entirely oc-
cupied especially in Posterior region by small
Carcinomatous nodules & small cavities Intermingled
Tissue infiltrated Pigmented. Towards
lower part there are groups of small Tuber-
culated Nodules & the lower lobe are
isolated Tubercles & two small cavities
Heart small & flabby & partly decolor-
ized in the right ventricle. Ant Segment

of Tricuspid slightly thickened at the Edges
Pulm: Semilunar valves Normal.
Walls of Left Ventricle of Normal thickness
segments of mitral valve slightly opaque
& few patches of atheroma over them. Aortic
Semilunar valves a little thickened
Aorta above Coronary Arteries Atheromatous
Above the Coronary Artery Yield Calcareous
Coronary Arteries from walls also athe-
romatous
Spleen very small. 60 grms. Pulp firm
small Adhesions distinct. Large amount of
Trabecula evident on surface
Left Kidney 130 grms. Capsule Strips with it small portions of sub-
stance & leaves the surface finely granular
Organ on section Bloodless Cortex diminished Renal vessels very apparent
Right Kidney 120 grms. Much the same appearances as left but capsule more adherent. 2 large cysts Half the size of a Walnut at upper end of Kidney. Contents of a dirty yellow Color.
Duodenum & Jejunum M.M. appears normal injected
Ileum. few & rare swollen solitary glands noticed. Ileo Cæcal
Liver. 600 grms At Portal & upper part of Right lobe is a mass of secondary cancer

about the size of a Horse chestnut. Another smaller mass about the size of a Marble exists to the Right of this. Another one the size of a Walnut exists immediately below the larger one in this Lobe

Section of liver substance uniform

Large veins do not contain much Blood

organ tolerably firm

Gall Bladder distended with a dark viscid Bile

Brain. Convolutions a little wider sulci broad. Vessels of Pia Mater do not contain much Blood. The External Exam organ looks natural. Arteries at Base calcareous.

Tongue almost entirely eaten away by Cancer. Base only remains. Cancerous mass involves tissues in lateral Region of the organ. Sub surfaces of lower Jaw are bound by the disease. Larynx not affected

Aneurism of Hepatic Artery 7/12/76 164

Case LIII Suppurative Hepatitis

William Henry aet 4

General appearance of body — Body that of a medium sized man. Rigor mortis present. Skin of a dirty brown color. sub-icteric

Thorax & abdomen. — 22 oz. of yellowish turbid fluid in abdomen oz. in the left pleura cavity

Right lung. — In a condition of collapse containing no air The pleura covered over with a thin layer of greyish yellow lymph. On section the lung is dark ailen & ~~solid~~ sodden. The anterior margin of middle lobe still contains a little air

Left lung — On the visceral layer of pleura, especially behind, are numerous small ecchymoses. On section the organ contains much blood, is firm & only slightly crepitant. The surface is batted with bloody, frothy exudate.

Heart — Right auricle filled with a large decolorized clot.

(over)

Right Ventricle — Tricuspid orifice appears large. Endocardium of a dark red color. Pulminary semi-lunar valves normal.

Left ventricle. — Walls appear of normal thickness. Mytral valve healthy. Aortic semi lunar valves, a little opaque ~~white~~ Blue deposit infiltrated. Heart weighs 270 Grammes.

Right Kidney weighs 200 Grammes. Capsule detaches with slight difficulty. On section the organ is very pale. Cortical substance ~~very pale~~ swollen Malpidgem tufts injected.

Left Kidney — Capsule detatches with slight difficulty. Organ contains more blood than the other. General appearance the same as the other.

Spleen weighs 445 Grms. Adherent to the stomach with thin capsule. Organ soft. On section of a dark red color contains much blood. Pulp soft & friable.

Stomach ___ Contains dirty mucous. Mucous membrane itself normal.

Intestines ___ Nothing abnormal noticed in small bowels. No trace of ulceration in the large intestine. The solitary glands are somewhat distinct in the cæcum & ascending colon to [illegible] pigmentation

Bladder ___ Nothing abnormal noticed in this organ. or about the prostate

Liver weighs 4879½ grms. 10.804. lbs. with the stomach attached. The peritoneal cavity in many places shows signs of recent inflammation. The left lobe of the liver is intimately adherent to the stomach by a thick layer of firm yellowish colored lymph. The right border of the organ is cemented to parts in its neighbourhood by lymph of a similar character. A small amount of exudation also exists upon the descending colon; the general peritoneal surface was not affected, the serous surface covering the intestines being clear and glistening. The liver itself retains the normal shape. The upper surface is smooth and not adherent. Towards the right border a large yellowish

colored swelling is evident, which to the touch fluctuates very perceptibly. Other less distinct yellowish spots are seen scattered over the organ. To the touch the upper and back part of the right lobe is exceedingly soft and fluctuates like a sac of pus. On the under surface many yellowish white nodules apparent, some large, others quite small; all distinctly fluctuating, a very large one is apparent on the under surface of the left lobe. A transverse incision through both lobes reveals the fact that we have to do with a diffuse suppurative hepatitis. An immense quantity of several pints yellowish white custard like pus flowed out. The right lobe is completely honey-combed by a series of small closely united abscesses, ranging in size from a marble to a walnut. The septa between these abscesses are composed of a dark red tissue, — the remains of the hepatic substance. Most of these small abscesses communicate with each other, some have merged together to form larger ones; they all possess distinct lining membrane which is frequently stained with bile. The cavities of the upper and posterior part of the right lobe are somewhat larger. One irregular yellowish red swelling, to the left of the anterior margin of the liver is found on section to consist of a number of these abscesses. The left lobe is in a similar condition and in both the abscesses extend throughout the whole thickness of the organ. The only portion comparatively free are the

Lobus ~~Hepatis~~ quadratus and that portion of the organ lying immediately above and a little to the left of the Gall bladder These parts on section are of a dark color, lobules distinct, small bile vessels very evident. The gall bladder is small, contains about three drachms of a ~~yellowish~~ clear somewhat viscid secretion. On pressing it and along its duct no fluid could be forced out at the puncta biliaria. A probe was with difficulty or indeed could not be passed in the cystic duct owing to the number of irregular folds of its mucous membrane which were evident when the duct was slit up. The common bile duct itself was patent, the mucous membrane of its upper two thirds stained with bile. There were no clots in the superior mesenteric, gastric or the splenic veins. On slitting up the portal vein itself a small tubercle projected into the calibre of one of the right divisions. The tissues in the neighborhood of these main divisions was infiltrated with pus. A firm nodule was felt at the portal fissure and mistaken at first for a bunch of lymph glands; on section, however, the cortex appeared laminated, and careful dissection of the parts about, revealed the presence of an aneurism of the right branch of the hepatic artery. The dilatation begins immediately beyond the Gastroduodenalis and extends about three inches as a ~~fusiform~~ somewhat conical swelling. The left hepatic arises from the obtuse end of the aneurism, and is unaffected. At its thickest part the circumference is three inches. For 2½ inches it passes to the right, then gives off two branches which appear occluded; then turns ~~at right~~ at right angles and passes backward for 1¼ inches towards the posterior border of the liver, and divides in to two branches which pass in to the central parts of the organ

Tuberculous Pyelitis & Nephritis

8/12/76

Case LIV Smith

P.M. 48 hours after death

Gen appearance

Body that of a slim delicately built young man Skin rough & harsh slight P.M. discoloration in dependent parts

Reporter CM & SJ

vol VI 66

Right Kidney. Organ small Lobulated Externally — To the feel made up apparently of Prominent cysts. On section the whole organ is seen to be converted into a mass of cysts containing a fluid in which numerous white flocculi are scattered. The fluid contained is not Pus. These cysts communicate with each other about the size of large walnuts & are about a dozen in number. The walls of these cysts in places are infiltrated with Tubercular Matter & are covered with a white Putty-like Material. On stripping off the capsule numerous Tubercular masses are found in the remnants of the cortex

Left Kidney Organ very large — more than three times the size of the opposite one. On Section — the Pelvis of the organ is dilated — The walls thick & covered with a dirty greyish exudation the calyces are also dilated & their walls in a similar condition. The Pyramids are injected & contain in many places small round collections of Pus. Throughout the cortex which is swollen numerous suppurating foci exist. Many of them — the majority of them are isolated — the larger about the size of Peas. Towards the upper end of the organ they are more closely aggregated & in one place fused into a large Caseous mass. On stripping off the Capsule the surface of the organ is studded over with similar Bodies — Many of them come away with the capsule looking like small Tubercles in its substance

Section of these white masses in the Kidney shows them to be firm usually solid throughout. occasionally softened in the centre in which case the Periphery is dense & it appears from the general condition of the organ that we have to do with a Tuberculous & not a suppurating Process

Bladder. Mucous Membrane roughened ulcerated The Healthy portions of the M M are reddened & injected. Fully three fourths of the M M is gone. The ulcerated surface has Bared the Muscular walls

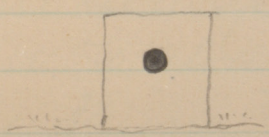

1.72
12/12/76

Case LV Cancer of Liver - primary

General appearance.

Body that of man between sixty and seventy years of age

Skin moderately jaundiced, Considerable emaciation skin dry and harsh. Veins indistinctly visible over the abdomen, which is greatly distended. Left leg swollen and oedematous as high up as the thigh. Skin of the posterior parts of the body of a dark red color, over the right knee cap are a number of small, subcutaneous extravasations of a light red color. Rigor mortis present in moderate degree

Thorax and Abdomen.

250 ounces of a yellowish bile-tinged fluid removed from the peritoneal cavity. Ant. margin of Liver "

√ Intestines of a dirty slate color, here and there small flakes of lymph are seen upon them. The descending colon passes down to about an inch and a half below the crest of the ilium, turns suddenly and passes up upon the kidney nearly to the spleen, at which point it is adherent by firm bands to the omental tissues, turning again, it passes obliquely to the lumbar vertebrae and descends in front of them and the sacrum to the anus. In the whole of this course it is closely attached. The ileum 2 inches from the valve is attached to psoas muscle by several strong bands, the head of the caecum is united externally to the tissues over the ilium, the diaphragm corresponds to third intercostal space on the right side, to the lower margin of 4th rib on the left

On opening the thorax the right lung collapses slightly, is not adherent, no fluid in this cavity.
Left lung appears universely adherent by tolerably strong old fibrous bands. Pericardium contains hardly any fluid. Subpericardial fat in small amount and deeply stained (yellowish) the vessels on the heart are plain. Veins tortuous and empty, veins full.
Right Auricle distended with grumous clots about 3iii of clots and blood removed from the cavity
Right Ventricle contains some partially decolorized clots and long thrombi extend into Pulmonary Artery on opening the Left Auricle about 3ii of dark blood and clots escaped from its cavity and Pulmonary veins. On removal of heart adhesions [illegible] escape from the Aorta and large veins. Tricuspid orifice of normal size walls of right ventricle thin tricuspid valves a little thickened at the edges and stained of a yellowish color. walls of left ventricle firmly contracted and look thick in proportion to the size of the heart
Mitral valves a little atheromatous towards their bases Cordae tendinae are fibrous and the apices of the musculi papillares are fibrous
Endocardium is opaque especially on the Septum Aortic semilunar valves are slightly opaque and atheromatous at their borders. The Aorta immediately above the valves present patches of atheroma
~~Left Lung~~ Weight of the heart 2¼ pounds
Right Lung Crepitant except at post. part of lower lobe. Pleural surface especially bluish is

Grand sev with small fibroid thickenings these are flat and chiefly on the outer lobular tissue, the majority of these not larger than pins head. One or two of these noticed to be double that size at posterior part of lower lobe there is an area about the size of a penny on which lobules are very distinctly mapped out by fibroid tissue on section the upper lobe contains much blood & frothy serum, the lower lobe posteriorly is serum, sodden, oedematous and almost airless, the middle lobe somewhat Emphysematous at the border sodden & oedematous towards the root (The small fibroid thickening on pleura noted too are seen in some instances ~~as~~ situated on small hemorrhagic bases.) Several of the pulmonary vessels are seen to be filled with small clots

Epicardium

Epicardium throughout, on visceral surface of this lung behind are one or two small fibroid thickening on section the lung contains much blood which with a frothy bile stained serum exudes from surface The arch & the aorta somewhat dilated Thoracic portion contains much blood and clots The omentum

Contains a moderate amount of
fat

Right Kidney Left Kidney 173 Grams
Organ firm Capsule detaches readily Two small white masses seen on cortex good deal blood exudes from surface Cortex of a dirty red brown color having also a slightly yellowish tinge

Right Kidney (153 Grams)
Large cyst exists close to hilus of the organ two small white nodules also seen in this organ. General appearance like the other.

Spleen
Firmly united to fundus of the stomach and to the tail of the pancreas the latter is united with the tissues in the hilus forming a firm hard mass sending small projections into the organ On section the substance is of a dark brownish red color. One small cyst about size of a pea exists beneath capsule filled with a dirty brown fluid. Upon which also some small fibroid thickenings are noticed. Spleen weighs 99 grammes

Stomach & Duodenum
Duodenum filled with dirty dark brown mass. On pressing common bile duct bile flows from the papilla Villiaris

Stomach contains a quantity of dirty dark mucus. Mucus membr: soft, tumified & pale – the vessels not full – along the fundus are several punched out ulcers. the bases of which are hemorrhagic – there are small (0 o 0), clearly cut, not inflamed, about 20 of them, noticed

Intestines – Mucus membr: of the jejunum of a very dark brown color. and the vessels contains a considerable amount of blood. – the upper part of the ileum is pale – the vessels of the lower part injected – The coats are sodden & edematous –

The mesenteric glands are not enlarged – The superior mesenteric artery is atheromatous – The abdominal aorta, iliac arteries are also atheromatous – The inferior vena cava contains blood – The ~~internal~~ femoral veins ~~artery~~ of the left side contains a firm thrombus – the right is free. The mucus membrane of the large intestine is congested, i.e. the veins are full.

Liver 4¼ lbs Organ closely adherent to the diaphragm behind, and at the right border. Right lobe also adherent below to the tissues in the neighborhood of the right kidney. Plump somewhat smaller than natural the shape of the organ is maintained. The superior surface is exceedingly irregular owing to the presence of numerous cancerous masses. A little to the right of the middle of the upper surface a large white mass is evident, which depressed in the centre. This mass

occupies an area fully three inches in diameter. Above the Gall Bladder there is another puckering and numerous nodules exist in the liver surface about it. An inch and a half to the right of the longitudinal ligament there are also two puckered depressions, and the whole of the surface in this region is involved in the disease. The posterior border is not so much affected; only here and there presenting isolated nodules. The upper surface of the left lobe presents numerous nodules, and two puckered depressions. Where the longitudinal ligament is attached to the diaphragm there is a firm extensive mass of the disease. The under surface of the right lobe is comparatively free - nodules being seen only at the anterior border. The Lobus Spigelii presents a single deep white puckering. Many elevated tuberous masses exist on the under surface of the left lobe. All of these masses are somewhat elevated above the surrounding liver substance, the majority of them presenting shallow cup like depressions.

Longitudinal section from right to left, through both lobes shows the central part of the liver substance to be the seat of disease. The larger white mass noticed on the right lobe extends fully two inches into the substance of the organ, and the whole of the tissues between it and the left border is the seat of innumerable nodules. Nearly 3/4 of the surface section being cancerous. The posterior border and under surface of the organ contain only a few nodules. The hepatic substance is dark and much blood exudes from the hepatic veins; the venae centrales of the lobules are uniformly injected, many

apparently much dilated. The Gall Bladder is involved in the disease, being surrounded about the middle with a white cancerous girdle and the fundus also being involved

LVI ~~Pneumonia~~ Phthisis

Dunlop. æt.

General appearance

Body that of a tolerably well built man. Rigor Mortis present. Post Mortem discolorations. Eyes slightly flexed. On opening abdomen - omentum completely covers intestines on lifting omentum up - Intestines appear beautifully injected

Position of abdominal viscera normal

Diaphragm corresponds to fifth rib

Ink Mammary line lines extends two inches below margin of ribs.

Opening thorax - Lungs do not collapse

Considerable amount of fat covers over pericardium

Right lung firmly adherent at apex & over the whole of upper & middle lobes.

Left lung adherent laterally by strong bridles. No fluid in either cavities.

Two ounces of amber colored fluid in pericardial sac.

A small patch of attrition on L of ventricle near the apex.

Right auricle occupied by a large clot upper part of which is discolorized

Right ventricle also filled up with clot & dark grumous blood.

Left auricle contains large dark clot filling cavity completely

Tricuspid orifice a little large. Clots woven with Chordae tendinae.

Pulmonary semilunar valves healthy

Mitral valve normal.

Aortic valve healthy.

Walls of left ventricle of normal thickness

Endocardium healthy.

<u>Right lung</u>, volume full. organ does not collapse on table. Upper lobe airless. On section a large cavity irregular in shape & about size of orange found at lateral part of lobe. Prolongations from this extend from this for 1½ inch towards anterior & quite to posterior part. This contains a small amount of a dirty purulent fluid & lined by a definite pyogenic membrane and across walls the remains of blood+vessels are seen
Pleura thickened over the cavity
Remainder of this lobe contains caseous masses, & in a condition of great infiltration

Middle lobe solid except at extreme edges. On section surface bathed with a quantity of pus which exudes from small cavities which are scattered through whole of tissue. Intervening lung tissue is infiltrated - air cells filled with exudations. Here & there small pellucid bodies evidently miliary tubercles

Lower lobe slightly crepitant at free margins & throughout substance

On section a dozen or more small cavities are seen from which pus exudes. Throughout tissue are numerous miliary granulations around which lung tissue is a little condensed.

Left Lung. —

Crepitant almost throughout. On section upper lobe near the root contains several small cavities and miliary tubercles are seen in their neighbourhood. Same tubercles also exist more or less throughout the whole of this lobe. The Lower Lobe especially above also contains numbers of these granulations. The Lung tissue itself contains a considerable amount of blood

Spleen

315 Grammes. — Organ soft. Pulp of a dark brown red color. Malpighian corpuscles somewhat swollen. ~~Kidneys~~

~~Left~~ Kidney.

315 Grammes. Organ firm. Capsule thin detaches readily. Venae stellatae moderately marked. On section much blood exudes chiefly from the vessels at the bases of the pyramids. Substance appears tolerably healthy.

Right Kidney

240 Grammes. General appearance same as the other.

Bladder & Ureters appear healthy. —

Stomach. Large veins appear full. Rugæ present Ulcers apices dark red in color Mucous membrane appears healthy. A small clot exists in the portal vein.

Small Intestines

Large Intestines

Nothing abnormal present

Liver

2330 Grammes Organ firm. Somewhat larger than normal On section a large amount of blood flows from the hepatic veins Lobules tolerably distinct The capillaries in the centre slightly injected The gall bladder contains a small quantity of dirty brown bile

Brain

Small clot in longitudinal sinus considerable amount of fluid in subarachnoid space. Veins of Pia mater full. Nothing abnormal noticed about base of brain Inferior part not examined, being kept for dissection

Bronchial glands Cancer

Bronchial gland considerably enlarged & turnified
& contain miliary granulations. None of them
were observed to be caseous
Aorta appears healthy

LVII Emphysema
Woodcroft Aged 60 years
General appearance
body that of a moderately
aged old man, Rigor Mortis not present
Chest barrel Shaped, Ribs bulge Anteriorly
on percussion almost tympanitic
sinus of the Skin full, Slight Post mortem
discolaration. feet a little Oedematous
Skin pale dry & harsh
Thorax and Abdomen
on opening the Abdomen the liver is
seen to stand about two inches below
the Costal margin the bladder
is much distended extending almost
to the navel, the diaphragm cor-
responds to the Seventh Rib. on
opening the Thorax the lungs do not
Collapse, on opening the pericardium
about three Drams of a clear fluid
were found in the Cavity, the heart
appeared large all the Chambers much
distended with blood
Heart
Rt Auricle distended with
~~Clots~~ soft gruinous clots the
foramen ovale is closed by a valvular
membrane which is deficient at one
side, Coronary vein distended foramina
thebesii very evident right ventricle

much dilated and filled with dark clots of blood, tricuspid orifice dilated admitting four fingers as far as the second joint, pulmonary valves normal left auricle about normal size contains dark clots, Left ventricle walls appear slightly thicker than normal muscle substance dark red endocardium slightly opaque, mitral valves normal aortic semilunar valves thickened firm & calcareous at their attachment at the commencement of the aorta just above the coronary arteries there are patches of atheroma above the anterior segment two calcareous vegetations about the size of peas project into the lumen one of these masses is attached by a pedicle the arch of the aorta itself is not atheromatously diseased. Heart, weight 375 grms. Right lung extensively adherent throughout its whole extent especially upper and anterior portions of this lung an excessive emphysematous at the anterior border. especially the air cells have merged together forming large irregular blebs on section a large quantity of frothy serum exudes in the upper lobe there is a

patch of solidified lung data in color, firm, pneumonic, the lower lobe below is in a condition of collapse and the portion of the lung contains an unusually large amount of fibroid tissue Left lung adherent throughout upper & anterior portions of lung excessive emphysematous, apex slightly puckered and contains a number of large dilated air cells on section the lung contains a large amount of pigment much blood oozes from the section a small patch of pneumonia exists in the upper part pulmonary artery much dilated the posterior part of this lung is sodden & oedematous Spleen organ small capsule scattered over with fibroid thickening, on section pulp firm, malpighian corpuscles not visible. Left kidney capsule detaches readily & leaves the surface of the organ tolerably smooth organ tolerably firm on section color uniform organ contains considerable amount of blood malpighian corpuscles distinct in one of the pyramids there is a small white nodule about the size of a pea probably tubercles Right kidney organ contains a number of small cysts adhesions the apices of the pyramid are filled up

with urinary salts the pelvis of the organ
contains numerous ecchymosis Small intestines
beyond a few ecchymosis nothing abnormal
noticed in small intestine large bowell appears
healthy mucous membrane of the oesophagus
appears healthy, Stomach almost empty
mucous membrane towards the pilorice end
there are about a dozen punched out ulcers
with dark red bases & raised borders one
of these ulcers exists at the pylorus Mucous
membrane of duodenum a little congested
The common bile duct free. Liver organ
small tolerably firm, capsule is the pect
over the gall bladder opaque on
section the central veins of the lobules are
injected Brain sulci wide & deep convolutions
somewhat wasted pacchionian bodies
large (Weight of brain 2 3 0 drs) sub arachnoid
fluid in excess vessels at the base slightly
over atheromised the organs appear generally
healthy (reserved for dissection)

11/1/76 1.88

LVIII Chronic Pyelitis. Struct. Ureter.

General appearance

Body that of a fairly well built man skin pale; slight post mortem discolouration patchily Rigor mortis present in slight degrees. Features present a very natural appearance

On opening the abdomen the position of the viscera was found normal Intestines of a pale slate colour. Omental fat moderate in amount

Heart: of full size. Right auricle contains dark blood and soft coagula. Right vent. full of clots, these near the walls partially decolourized. Mouth of orifice of normal size; valves healthy; pulmonary semi-lunar also healthy. Left ventricle contains a small firm clot. walls of average thickness. mitral and semi-lunar valves natural. one segment of the latter penetrated

Lungs

Nothing abnormal noticed about these organs, no nodules or tubercular masses

Spleen

considerably larger than usual. Pulp soft, dark red in colour, friable. Malpighian corpuscles indistinct

Liver

does not extend below the margin of the ribs. It is firm to the touch, pale and

Stomach & intestines not examined. No congestion of Peritoneal

Kidneys & Bladder.

On removal of the intestines the bladder was seen to be dilated & tending to a level with the pubis The right ureter, seen as a tortuous dilated vessel about the thickness of the thumb.

The left kidney is large, above the average size. The capsule tears off easily leaving a slightly mottled surface. On section the pyramids are injected at the bases, the cortex ureter healthy lines; the proportion between the two being natural, The right organ is felt to be small, soft to the touch & fluctuating Colour dark externally. It was removed with its ureter & the bladder & on section presented the following appearance

Case LIX 190

Ovarian Tumor. (Operation.)

Matilda Larocque act. 24. Single.

General Appearance.

Body that of delicately built girl, Rigor mortis present. On abdomen, extending for about 6 inches in median line, is a longitudinal incision at lower bottom part of which the pedicle of the tumor is attached.

On opening abdomen,

Omentum covers over the upper part of coils of the intestine Parietal peritoneum, is injected, here & there ecchymotic, & the coils of intestine are adherent to it, by thin flakes of lymph, and they are very generally coherent to each other. Coils of small intestine are very generally adherent to each other.

About 3ij of bloody fluid in cavity of peritoneum. Position of thoracic viscera normal. About 3ij of fluid in pericardial sac. Right heart contains fluid blood mingled w gruemous clots. Small ante mortem clot in cavity of R. ventricle. Left ventricle walls of normal thickness, Valves, (mitral & semilunar) normal.

Left Lung.

Pleura, covered over w few ecchymoses espec. in lateral region. Lung crepitant throughout except small portions of collapse on posterior part.

Right lung

Pleura ecchymotic at apex, & between upper & middle lobe. Organ crepitant. Two small

clause

patches of apoplexy at apex, not extending far into sub-
Spleen. Capsule opaque, very thick at one
small spot, tissue firm
Malpigian bodies distinct
Kidneys, of average size. On section present a toler-
ably healthy appearance. Cortex a little pale.
Stomach, contains a small quantity of fluid & mucus, smelly
slightly of brandy. Mu. M. soft. Lining fluid towards the pylorus
Intestines
Appear quite healthy, tumour had not
seem attached to them
Uterus
Small - Right Ovary appears
normal no cysts Left Ovary disappeared
with the tumour
Liver
Normal size Tissue soft - Considerable
amt of blood oozes from vessels
on section - Section surface
has a greasy look.
Stomach
Contains small quantity of
mucous with powerful smell of
Spirit —

The tissues in the anterior wall of the pelvis were red-
dened, in places hemorrhagic, and several drachms of
blood existed between uterus & bladder. General oozing
had taken place apparently from the surfaces to which
the tumour had been adherent

LX Pneumonia

~~October~~ January 11th 1877

Edward Foran aet. 20 years
Admitted January 6th /77 Died Jany 11th

Body that of a well built muscular man
Slight postmortem discolorations on the dependant parts
Thorax and Abdomen
Position of abdominal viscera normal
Liver extends about ½ inch below costal border
No fluid in either Pleural cavity —
About 3iii clear fluid in pericardium
Heart
Right Auricle distended with a large dark clot. Orifice of veins natural
Right Ventricle Contains about 1/3 fluid blood. and a tolerably large antemortem clot is intertwined in the Columnae Carn —
Tricuspid orifice appears a little large — Segments of the valve normal
Left Auricle Contains a quantity of dark semicoagulated blood
Left Ventricle Contains a firm decolorized clot and some dark ~~ru~~ serous blood Walls of ~~Left~~ Ventricle of full thickness

Mitral Valves - normal

Aortic Semilunar valve also normal

Left Lung - weight 560 grammes
Fills in volume does not collapse when laid on the table - No adhesions
Organ moderately pigmented
On section - a large amount of serous fluid bathes the surface
The upper lobe is very edematous
Lower lobe contains more blood
All parts of the organ float and contain air

Right Lung ~~colon~~ uniformly adherent to diaphragm and chest wall and removed with difficulty
Weight 1880 grammes
Whole organ firm Solid & perfectly airless
Pleura covering lower half of upper lobe and anterior part of lower lobe in front is covered over with a thick layer of false membrane, pink & white in colour. A similar layer white & fibrinous exists between the diaphragm and the lower lobe
The middle lobe and upper part of upper lobe are not covered by membrane
On section the organ is seen to be

in a condition of red hepatization.
In places passing on to a condition of
gray infiltration
Middle Lobe Still Contains a small
amount of air near the root, and partially collapsed
Liver Organ firm appears larger than
Natural Contains on section a large
amount of blood. —
Lobules indistinct —
Spleen — of Moderate size — pulp soft —
Vessels contain much blood
Weighs 250 grammes
Kidneys Large. capsule detaches readily. surface marked
with stellate veins. On section contains much blood. pyramids cortex of
uniform red colour. Medullary rays of the latter evident in places

Inferior Vena Cava Contains a dark
Coagulum
Stomach
Full of half digested food
Rugæ injected Large veins full
Nothing abnormal noticed in the intestines. large or
small

LXI Progressive Pernicious Anaemia

15/1/76 1.96

Autopsy.—Thirty-two hours after death.

Body that of a well-built man of fair muscular development. Hair grey. No emaciation; panniculus adiposus well developed, especially over abdomen. Skin of extraordinary pallor,

with slight lemon tint, the shoulders marked with patches of deeper yellow hue. A few old psoriasis spots seen in the region of the elbows and knees. No petechiæ. Lineæ albicantiæ in the skin of groins, and upper and outer aspect of thighs, and on the outer edge of anterior folds of axillæ. Fingers slightly clubbed, and the nails of both hands markedly incurvated. Rigor mortis moderately well marked. Post mortem stains scarcely perceptible. No enlargement of the superficial lymphatic glands. No cadaveric odour.

Brain.—Not examined.

On making the preliminary incision a layer of deep yellow fat, fully an inch in thickness, is cut through over the abdomen. Muscles of the thorax of a remarkably healthy red colour. In the abdominal cavity the position of the viscera normal. Omentum moderately fatty. In the thorax a considerable amount of fat over the pericardium. The left pleural sac contains twelve ounces of bloody, yellowish-tinged, serum. A few strong adhesions posteriorly. In the right pleural sac ten to twelve ounces of fluid of the same character. Adhesions more numerous at apex and sides.

Pericardium.—Contains six drachms of a yellowish, bloody serum. No ecchymoses on either leaf.

Heart.—Large, excessively flabby. Sub-pericardial fat abundant about the base and in the anterior ventricular groove. Patch of attrition over upper part of right ventricle in front, and another behind, near the inferior vena cava. On opening the heart in situ an ounce of blood, with one small coagulum, in the cavities of the right side, and ten drachms in those of the left. Organ flaccid, and walls collapsed when laid on the table. Right auricle normal. Right ventricle somewhat dilated, the endocardium stained by imbibition. Tricuspid valves a little thickened and gelatinous at the edges; orifice of normal size. Pulmonary semi-lunar valves healthy, one segment fenestrated. Cavity of left ventricle large, walls of normal thickness. Mitral valves quite healthy, a little stained; orifice of proper size. Aortic semi-lunar valves a little opaque; slight atheroma at their bases, and on the aorta opposite their

free borders. Sinuses of Valsalva very distinct. Nothing abnormal in the left auricle. Muscle substance of the organ exceedingly pale, having a yellowish, faded-leaf appearance, especially marked in the walls of the left ventricle.

Aorta., both arch and trunk of full size. Beyond the left sub-clavian there is a flattened patch of atheroma, about the size of a half-penny.

Lungs.—Deeply pigmented; crepitant throughout; lower lobes œdematous and dark in colour posteriorly. The mucous membrane of the *Trachea* at the bifurcation, and extending irregularly nearly to the larynx, is represented by a number of bony plates, lying immediately upon the cartilages, which are themselves very dense, and partially ossified.

Spleen.—Weight, six ounces; soft and flabby. Capsule a little opaque. On section, pulp soft, of a light brownish-red colour. Trabeculæ distinct. Malpighian corpuscles not evident. Very little blood in the organ; none could be obtained from the splenic vein.

Left Kidney.—Length, 5 ″. Unusual amount of superficial fat. Capsule loosely attached, and on removal leaves a very anæmic-looking organ. No atrophy of the cortex, which is pale and bloodless. Pyramids, except at the bases, also pale. *Right Kidney*, 4½ ″ long, dark red in colour, uniformly congested, forming a striking contrast to the other. Capsule easily detached; stellate veins prominent. On section, both cortex and medulla contain much blood.

Supra-renal Capsules.—The right is soft in the centre, and somewhat larger than the left, but nothing unusual about either.

Bladder.—Distended with pale urine. Mucous membrane healthy looking. Prostate gland of full size.

Tonsils and glands at root of tongue not enlarged. Several ecchymoses beneath the mucous membrane of the anterior wall of the pharynx. *Œsophagus* presents nothing unusual; a few small extravasations are noticed near the cardia.

Mucous membrane of *stomach* pale, and at the cardiac end thin; at the pylorus it is thicker. *Duodenum* healthy; common

Progressive Pernicious Anamia

15/1/76 1.96

bile duct is pervious. *Jejunum* contains a quantity of dirty yellow mucus. Mucous membrane is pale. In the *ilium*, Peyer's patches are scarcely perceptible; the solitary glands towards the ileo-cæcal valve are alone distinct. In the *large bowel* the mucous membrane is anæmic. No ulceration. Scybalæ in transverse and descending colon.

Liver.—Rather small, of a light yellow colour, especially in the left lobe. Capsule smooth. On section a small quantity of liquid blood is seen in some of the hepatic veins. In places there is a very slight injection of the intra-lobular veins, which relieves the otherwise uniformly pale surface.

Gall-bladder.—Full of dark tarry bile.

Pancreas.—Looks healthy.

Abdominal blood-vessels almost entirely empty. No blood in inferior vena cava or aorta. Intima of both healthy-looking. *Thoracic Duct* pervious throughout. Mesenteric and retro-peritoneal *lymphatic glands* small, the former unusually so, requiring considerable searching to obtain any. The amount of blood in the body appeared remarkably diminished, and it was only by pressing along the limbs that sufficient could be obtained from the veins to fill a small homœopathic phial.

Piece of the sternum, the upper half of right fibula, the inner third of left clavicle, half a rib, and one of the last dorsal vertebræ were removed for the examination of the marrow. Blood was collected from the heart, and junction of left jugular vein with the sub-clavian.

A striking feature in the autopsy is the extreme anæmia of the organs, their almost entire bloodlessness, and consequent pallor, the right kidney excepted

HISTOLOGICAL EXAMINATION.

The blood taken from heart and veins shows the same general characters noticed during life. Prolonged examination of different specimens made for this special object resulted in the detection of two nucleated red blood corpuscles.

Heart.—The fibres are in a condition of extreme fatty degeneration, the striæ being obscured by the number of densely

crowded droplets and fine molecular fat; only here and there a fibre occurs in which the striæ are faintly seen. In teased preparations numerous short bits occur, together with oil-drops and granules of fatty matter. In places there appears to be a good deal of interfibrillar connective tissue with fat cells.

Muscles of the Trunk.—The fibres of the thoracic muscles—which were observed to be of such a natural appearance—present no trace of fatty degeneration.

Spleen.—The ordinary corpuscles of the pulp, together with elongated, sometimes branched, cells of the retiform tissue are the chief elements seen in teased specimens. The red corpuscles have lost their colouring matter. A few cells containing red blood corpuscles are seen, but no nucleated red cells.

Kidney.—Teased preparations show the epithelium of the tubules, both in the cortex and pyramids, covered with fatty matter in the form of minute drops and fine granules; nowhere, not even in the large collecting tubes, are the cells distinct. The Malpighian corpuscles also contain many granules and small oil-drops, and the same exist abundantly in the field.

Liver.—Cells are stuffed with oil-drops; none noticed without them, while in many the protoplasm and nucleus are entirely obscured. Free fat exists infiltrated between the cells, and in the field. In a few, bile pigment is seen.

Mesenteric Glands.—Teased portions present a large number of perfectly normal-looking lymph corpuscles, among which the connective tissue elements occur in the usual proportion. Many of the small vessels and capillaries have their walls uniformly studded with fat grains, and may be traced as dark branching lines. In others, the deposition is not so extensive.

Nothing abnormal observed in the axillary lymphatic glands.

Medulla of Bones.—The marrow of all the bones examined—sternum, ribs, clavicle, vertebra, fibula—is of a dark violet-red colour, thick, about the consistence and colour of the spleen pulp in fever. In the clavicle it is more diffluent, of a lighter red colour, and to the naked eye looks a little fatty—an appearance not noticeable in the other bones, not even in the shaft of the fibula.

15/1/96 1-96

Progressive Pernicious Anaemia

15/1/76 199

LXII Diabetes. Lobar. Pneumonia

General appearance. Body that of a tall, delicately built man. slight P.M. discolouration in dependent parts. Emaciation moderate Rigor mortis absent

Thorax & abdomen. Position of abd. viscera normal, but stomach much distended. No fluid in either pleural sac.

Pericardium contains 3ij of citron-coloured fluid

Heart. R. auricle distended with a decolourised clot. R. ventricle also contains a large a. m. clot which are closely adherent & interwoven with the chordæ tendineæ & Col. carneæ

Tricuspid and pulmonary orifices & valves healthy.

L. vent. also contains firm white thrombi, which extend into the aorta. Mitral and aortic semilunar valves healthy, the segments of the latter fenestrated. Muscle substance of heart of good colour & normal in thickness

Right Lung. weight 8.20 grammes. Pleura - lateral part of upper lobe is occupied by a large irregular cavity, somewhat elongated, ~~about the size of a walnut~~ holding about 3ij. The walls are ill defined being made up of a dirty grayish brown pasty material, caseous in character

The lung in the immediate neighbourhood is almost airless, darkened in colour & much blood & serum exudes from the surface. There were no chronic changes in the lung about the cavity, which was situated in healthy tissue in the first stage of pneumonia. almost the whole of the lower lobe of this lung is in a condition of red hepatization; the anterior part of upper & whole of middle lobe are alone crepitant

No nodules or tubercles in the lung. - Left Lung 1320gms upper lobe emphysematous ant. part border; the rest of lobe is dark in colour, heavy, surface on section tabled emits fluid blood serum whole tissue dense. Entire lower lobe in condition of red hepatization

Spleen weight 160 grms

Organ flabby, on section pulp consistent colour dark brownish red. Mal. bodies indistinct

Left kidney 280 grammes. Organ large, capsule removes easily on section proportion between cortex & pyramids normal. Bases of pyramids reddish & congested, lines of tissue running into cortex

Right. 267 grms. Cortex somewhat pale. Malpighian tufts and few small vessels alone evident. Vence stellulae over both organs very distinct, & the small vessels form a beautiful mosaic work. Organs thought large appear perfectly healthy.

Liver. 1900 grms. Appearance remarkably & natural.

Consistence good. Veins full. Lobules somewhat indistinct surface section uniform, here & there the intralobular veins are well marked. Gall bladder empty. Bile duct pervious

Stomach

Contains a small quantity of dark half digested matter M. M. pale, mapped out by lines or small fissures into irregular areas. Small intestines healthy. Transverse & descending colon present many small follicular ulcers.

Brain. Nothing unusual noticed about the organ. The section was thought leathery, did not contain much blood. The parts about 4th vent. looked quite natural.

LXIII Phthisis Chr. Jan 16th – 77

John Hinn Aged 35 Admd Jan 16th – 77
7 1/2 hrs P. M.

General Appearances

Rigor Mortis present. to a very slight degree. Slight Emaciation Skin dry & harsh with dirty muddy color. Ankles (Endematous) & both legs on the posterior part to Middle of Calf in left leg it Extends & to Scrotal region thorax & Abdomen. Liver extends two inches below the Costal border in Mamary line Stomach distended with gas. Slight Amt of fluid in Peritoneal Cavity. In thorax recent hypostasis is seen Lower over left half of pericardium. Right lung adherent at apex & posterior border & upper lobe. 25 Oz of bloody serum in left pleural Cavity. Lung in this side adherent slightly in its upper half. 2 Oz of fluid in pericardium. Heart Right Auricle is distended with blood. Right Ventricle contains some decolorized Clot. Tricuspid a little dilated. Valves normal. Left Ventricle contains a few small Anti-Mortem clots.

Mitral valve healthy, base of anterior segment sectum atheromatous. Aortic semi lunar valves healthy
Muscular tissue of Heart appears good color & consistence.

Right Lung -

On section, the central & lateral part of upper lobe occupied by a number of irregular communicating cavities. these cavities are very irregular, have a distinct lining membrane which is traversed by the remains of bronchi & vessels - the capacity of these cavities will be about two oz. Throughout the remainder of this lobe is occupied by numerous groups of tubercles, about which the lung is pigmented & towards the apex, some of these are softing into cavities

Anterior margin of this lung - is slightly emphisematous. Anterior half of lower lobe is airless - firm to touch, surface bathed & brown - presents the finely granular aspect of Pneumonic ~~Congestion~~, consolidation
The Posterior part of lobe is engorged, slightly oedematous - & upper & back part, contains numerous aggregated tubercles, & one small cavity

Left Lung -

Intimately adherent to chest wall - Parietal pleura being removed with it - Almost whole of lung is covered over a plumitic exudation, firm, solid. At lower &

anterior part the lymph is much more recent & surface of lung in contact c diaphragm is completely covered over c lymph. Lung is diminished in size

On section thro. lung – is seen to be almost converted into a mass of cavities. a large one the size of an orange, exists in apex – two others nearly as large, in the anterior portion – The lower lobe contains a large cavity at upper part. no portion of this lung is crepitant – The parts unoccupied by cavities contains numerous nodules & tubercles, ~~so~~ surrounded by congested tissue –

Spleen, weight 360 grms.
organ dark red color. Pulp moderate consistence – surface uniform. Malpighian bodies indistinct, good deal blood in organ

Right Kidney – weight 250 grms – organ large, very dense capsule detaches with slight difficulty cortex pale. bases of pyramids are only congested – organ looks in condition of amyloid degeneration, though iodine does not give the charac. reaction

Left Kidney, weight 310 grams ~~&~~ not so large – presents same characters as other kidney

Liver – weight Right lobe marked in an oblique direction by the ribs, on section, the organ is firm & contains a considerable amt. of blood. lobules distinct. Central veins congested. Does not look fatty

Gall Bladder contains a small quantity of tarry bile

Stomach – empty. Pyloric extremity. mucous mem –

brane a little injected, easily torn & moderate thickness
~~Do~~ Duodenum healthy, nothing abnormal
noticed in jejunum - In Illium are two patches
of Peyer empested & commencing to ulcerate
Nothing abnormal noticed in large intestine, or ul-
cerations -
Bladder. nothing abnormal -

22/1/77 205

LXIV Geo. Franklin. Abscess of Brain hr. P.M.

General appearance.

Body that of a well built muscular man. rigor mortis present. p.m. discoloration in dependent parts. Eyes sunken, pupils of average size, left somewhat larger than right. Jaws firmly clenched. upper lip presents some small dark scabs on the mucous membrane

- Brain -

Soft parts of the scalp contain a moderate quantity of blood. Calvarium tolerably thick especially in the anterior part On removing ~~the calvarium~~ it the vessels of the dura mater and numerous bloody points exist on the surface are seen to be full. Longitudinal sinus contains fluid blood and posteriorly a few small clots. On removing the dura-mater the arachnoid over the sulci is distended and a good deal of lymph is seen along the course of the vessels in the neighborhood of the longitudinal ~~fissure~~ more especially about the anterior fourth and over the left hemisphere. On attempting the removal of the brain the finger perforated an abscess in the left frontal lobe from which some dirty looking reddish pus escaped. On removal this was seen to extend from within one half an inch of the cortex to the under surface of the lobe ~~this extended~~ passing in an oblique direction from above downwards occupying chiefly the anterior and lower portions of the lobe. It extends fully one inch and a half from the anterior border of the lobe its length is fully three inches breadth not more than three fourths of an inch. The abscess is occupied by pus broken down brain tissue and blood the margins are ill defined the walls ~~of the abscess~~ being made up of

disintegrated brain tissue occupying the corresponding lobe on the other side is another abscess this extends for about an inch and a half along the upper border and internal surface of the lobe it then descends occupying an area immediately within the gray matter of the anterior border this descending portion is about an inch and a half in length by one half an inch in thickness A quantity of purulent lymph binds the two frontal lobes together Purulent lymph also exists upon both upper and under surfaces of the cerebellum along the base of the brain in the neighborhood of the optic nerve Lymph also extends in the course of many of the vessels in the lateral portions of the hemispheres The veins of the pia mater are moderately full, and the small vessels over the convolutions are also distinct from the puncta vasculosa of the centrum ovale ~~blended~~ & nodes & plexus over the adjacent white substance.

LXV Typhoid Fever? 10 hrs P.M.

Catherine Clarke. æt. Had been confined 24 hrs ante mortem

General appearance. Body that of a well built. stout woman.

Face livid, dusky, eyes open. Abd. prominent. Linea albicantes in lower abd. region & lateral, & upper aspects of thighs. Posterior parts of body deeply stained. Rigor mortis present

Thorax and Abdomen.

Transverse colon & Stomach much distended with gas & very prominent. Omentum thin, moderately fatty. Uterus is seen to project above the brim of pelvis

No fluid in either pleural sac.

3½ ℥ fluid in pericardial sac

Heart. Right. Auricle contains a quantity of dark fluid blood. Right ventricle contains a few clots & fluid blood. Tricuspid valves and orifice normal. Pul. semi-lunar also healthy

L. ventricle. Cavity empty. Mitral valves. quite normal. Aortic semilunar the same. Muscle substance firm & natural

Lungs. Left. upper lobe crepitant throughout & except at post border where there is a patch of collapse. On section numerous small patches ~~of~~ & at post. & ant. part. Lower lobe, dark, pulmonary & collapsed, contains also much blood on section. At upper & back part are several small apoplectic spots. Right. crepitant throughout

Pulmonary dark in colour. Contains much blood. Surface tinted with a dark bloody serum. Ant. part looks natural 2-3 minute aggregations of pigment in the pleura. The largest in upper part of middle lobe. Near lower border of middle lobe 2 small circular projections, white in colour, firm to the touch, about the size of peas. On section they are firm, & contain a hard dense nucleus surrounded

by cretaceous matter.

Spleen. 300 grammes. very flabby and soft. On section, tissue of much red colour, soft in the centre, almost diffluent. Malp. corpuscles indistinct, organ contains a tolerable amount of blood.

R. & Left Kidney. 250 grms. Organ flabby, capsule detaches with some difficulty. On section considerable amount of blood. Vasa recta congd. Malp. corpuscles distinct, surface mottled vasa stellata well marked. Left. contains rather more blood. but general appearance the same. Pelvis contains sinous mucus

Stomach contains a quantity of dark green matter & mucus membrane is covered with a tenacious mucus. Congested areas at fundus near the cardia. Duodenum healthy. D. com. choledochus patent. Ileum contains a quantity of dirty green faeces. No enlargement or congestion of Peyers glands. Sol. segmented

Large intestine. Nothing abnormal noticed. Lenticular glands somewhat distinct in places.

Vagina contains some recent coagula.

Uterus about twice the size of the fist, flabby. On section cavity is large, walls uneven, the anterior a firm tenacious chitinous adherent which was with difficulty removed & appeared to send prolongations into some of the uterine veins. Neck of uterus long. Hypertrophied

Brain. Vessels of pia mater moderately full. Organ firm pinkish & substance perfectly natural looking.

Case LXVI Morbus Brightii. (small cont. kidney) 24 hrs P.M.

I. at 20

Body that of a slight- delicately built-girl. Skin pale waxy No Anasarca. Abd. inflat. Rigor mortis absent. Body not emaciated

Thorax & abdomen. Viscera of abd. viscera normal. Intestines pale. light-premit. No fluid in peritoneum. Lungs pale. a few Ounces of fluid in pleural sacs.

Case LXVII Pleurisy. Fibroid & Fatty Heart.
H. H. W. at 65

Body that of a tall fairly well built man. Face somewhat emaciated. Feet ankles & legs swollen, & pit-in pressure. Thorax & abdomen.

About a pint & a half of clear fluid in the peritoneum. Viscera in normal position but the liver is pushed down 1½ inches below the ribs in the mammary line.

Fully 2½ pints of clear citron yellow fluid in the right pleural sac. The parietal pleura in this side was much injected & in colour covered by some few flakes of lymph. The chest was tapped (previous to removal), and on removing the sternum a definite pocket was found from which the fluid had been removed. The upper walls of the compartment were composed of thin membrane of lymph, recent, but evidently tenacious. Another of these pockets existed at the upper & anterior part of the pleural cavity. The visceral layer was also covered in places with recent lymph. and in the fluid removed there were some flakes. There was no fluid in the left sac and the lung was only adherent at one spot ~~towards~~ at the apex base

Pericardium. covered by a small amount of fat, and the tissue over it in the ant. mediastinum was infiltrated & gelatinous. Membrane thickened, opaque. 3ii of citron coloured fluid removed from it. Patch of atheroma over liver & anterior part of left ventricle

Heart looks large, & the cavities are distended with blood and grumous clots & tend into the veins

In the right auricle the appendix contains a very firm ante-mortem clot, colourless & intimately adherent to the muscular

pectinati. Right ventricle appears dilated. Tricuspid orifice large, about 5 p" in circumference. Valves healthy Pulmonary semi-lunar also. Coagula in left auricle which extend into pulmonary veins. In the left ventricle besides a large block coagulum, there is a layer 3/4" thick yellow stratified fibrin adherent to endocardium on its anterior aspect & to the septum. About the inner half of the muscular wall of the ventricle at this point has lost its normal colour & aspect, & is pale, almost white (at least light grey). It is tough, crumbles under edge of knife & is anæmic looking. The muscular wall & lateral to this looks healthy The general aspect of the entire ventricular walls was not so at the spot above noted - remarkable the colour was dark reddish brown. The Columnæ carneæ at their bases are whitish owing to degenerative changes which can be seen through the lining membrane. Inwards their apices they are firm, evidently fibroid & cut with difficulty
Bounding the septum

Mitral valves are healthy, the orifice of natural size. The semilunar thickened at bases & at the insertion of one of them is a thin narrow vegetation ring. Their edges normal; the valve is competent.
The aorta from the arch to its bifurcation presents numerous raised patches of atheroma, ranging in size from a pin's head to a shilling. In section of one a thick mass of yellow material is seen immediately beneath the intima

Spleen, slightly smaller than natural & presents two deep irregular fissures at the anterior border. It is exceedingly firm & dense, cutting crisply & with resistance. The trabeculæ are very evident; the pulp solid, dark brown in colour, corpuscles not visible

Kidneys. Of normal size. Capsules remove without tearing the substance. Cortex coarse, a little granular, & in the surface the points of entrance of the stellate vessels are depressed. Much blood in the vessels at the base & in the vasa recta, of pyramids

Liver. Surface looks a little irregular, Organ about normal size. On section tough, the surface markedly nutmeg, the hepatic capillaries being much distended, & the pale interlobular areas small. No stones in Gall-bladder

Intestines appear healthy. Brain not examined

Case LXVIII. Phthisis

Amelia Cairo ast 42

Body that of an averaged sized women, Emaciation, moderate. Skin hard and dry, face and arms Covered with freckles.

Legs. Under part of thigh very Edematous, on the anterior surfaces of feet and about the ankles are a dozen or more superficial ulcerations

Chest narrow ribs prominent

Thorax and Abdomen.

22 oz of clear fluid in the pentoneal cavity

Liver extends about two inches (2) below border of ribs.

Position of Abdominal Viscera.

Upper normal, in the left pleural cavity are about 44 oz of slightly turpid serum, right pleural sac obliterated.

Pericardium Contained 3j of fluid Over the sinus of right auricle there is a patch of attention a similar one, thinner and not so distinct exists over anterior and upper part of right ventricle

Upon opening right Ventricle a Quantity of dark Coagulated blood is found, the clots extend into the veins. The right ventricle contained a clot which extended into the Pulmonary Artery. Small amount of blood in left Auricle. Nothing abnormal in Cavity of right auricle. Tricuspid orifice normal size Valves healthy Pulmonary & Semilunar normal, one segment fenestrated

Left Ventricle

Wall full thickness Muscular substance firm, red color. Apices of papillae slightly fibroid, the free edge of Auriculo-ventricular valves of both segments of Mitrals, present. a few row of small Cauliflower excrescences, these are attached by narrow bases and are very firm The Aortic Semilunar valves are a little opaque but otherwise healthy, Endocardium & Septum opaque

Left Lung.

The whole of the apex was occupied by large irregular cavity the size of an orange divided imperfectly into compartments by fibrous Septa The walls are thin and at the apex are lost on removal The anterior part of this lobe is stuffed with nodules of tubercles in every stage of degeneration The Pleura Covering lower lobe is roughened and small capillary

The upper part of the lobe contains numerous nodules of tubercle and one small irregular cavity Lower part of this lung contains much blood, oedema and scattered tubercles

Right Lung.

Almost the whole of upper and middle lobe except the anterior border is converted into a large cavity The walls of Anterior and ~~Posterior~~ outer parts are tolerably thin. The root of lung is traversed by remains of Bronchi and blood vessels. (There is an extension of this cavity into anterior portion of middle

lobe occupying nearly the whole of it. At the upper and posterior of lower lobe, there is another Cavity the size of a small apple, scattered throughout the remainder of the tissue of this lobe are numerous tubercles. Bronchial glands and pigmented Mucous

Spleen.

weighs 185 grammes, organ firm and Consistant of a normal red color. ~~Malpighian~~ Malpighian Corpuscles indistinct.

Left Kidney

weighs 133 grammes, Capsule a little separates the entrance slightly on removal, on section the Cortex is Anemic, Coarsely granular Pyramids Contain the surface of this organ is rough and irregular and one or two white spots on surface of tubercle.

Right Kidney.

weighs 133 grammes and Corresponds in general appearance with the other.

Jejunum.

presents at its lower part a number of small ~~tubercular~~ tuberculous ulcers and similar ones exist throughout the Ileum to the valve, they are small none larger than a shilling, edges elevated, base thickened, these ulcers are most numerous in the Ileum, they Corresponds in all respects to the tuberculous ones. And the Peritonial surface ulcers may be seen numerous small tubercles

Uvula looks dark from fatty degeneration

Liver

Organ elongated in antero posterior diameter, fatty and in a nutmeg condition

Stomach

Contains some dirty

mucous membrane somewhat tubified, in large interlines these tuberculous ulcers also occur.

Larynx. Vocal cords ulcerated across at their post. attachment, this ulceration extends along the inner border of the arytenoid cartilage & ward towards the Rima, there is also ulceration at the ant. attachment of left vocal cord. Immediately below vocal cords is slight superficial ulceration on undersurface of Epiglottis there a few superficial loss of substance.

LXIX. Typhus Fever

See C. M. & S. Journ.
p 145 - vol 6

Case LXX. Died

Body that of a plump well nourished child. Skin pale, slight P.M. discoloration in dependent parts. Skin about mouth livid. Rigor mortis present. Feet strongly flexed.

On opening the abdomen liver extends 2 inches below the ribs, in the mammary line. Diaphragm corresponds to the 5th rib. About 3iv clear serum in the right pleural sac. None in the left. Pericardium contains about 2 drachms.

Heart

R. Auricle dilated, Containing decolorized clot and dark fluid blood.

R Ventricle also full of large Antemortem clot interwoven with fleshy columnæ and Cordæ tendineæ of the valves.

Left Ventricle. Contains a few purulent clots, to which decolorized one is attached to the Septum and passes up the Aorta. The walls of L. Ventricle is large, muscular substance of heart, especially in the right ventricle looks pale. On the removal of the organ a large quantity of fluid blood flows from the cut vessels.

Left Lung

Very feebly crepitant except at anterior margins. Lower lobe dark in color, firmer than normal and on section much blood escapes from it.

Right Lung

Posterior parts dark in color, do not crepitate much, contains a good deal of blood.

Portions thrown on water still float. Upper and middle lobes of a greyish red color and contain a good deal of serum. Both lungs firmer than natural and do not contain much air.

Spleen

Both ~~the~~ somewhat enlarged passing transversely is a deep fissure which almost bisects the organ another small fissure exists also and parallel to this ant. and lower borders are also irregularly notched On section the tissue is firm, dark red in color Malpighian corpuscles distinct and white

Left Kidney

Organ large weighing 63 grammes. Capsule thin and detaches readily. On section Cortex very distinct from the pyramids the former is swollen and anaemic Malpighian corpuscles faintly visible The pyramids are dark red in color with tubae rectae very distinct

Right Kidney

weighs 63 grammes. Some distinction between Cortex and medulla. In both organs veins and vessels at the base of the pyramids contains much blood

Ureters

Normal

Bladder

Formly contracted, contains no urine

Liver

Appears ~~congested~~ large. Of a dark reddish color On section contains much blood. Peripheral parts of lobules congested Gall bladder contains a couple of drachms of viscid yellowish bile

the walls infiltrated and gelatinous looking

Stomach contains some curds and a quantity of mucous. Mucous Membrane is soft and not corroded

Duodenum and

Common bile duct benious from middle part examined extending down through the Abdomen Peyers patches are distinct and Rudders tumified with the exception of a very large one just above the Ileo-Caecal valve in which a few of substance may be seen, some of these patches are ulcerated. Lips of the Ileo-Caecal valve are swollen and distinct and Ascarides Lumbricoides in Jejunum and 5 or 6 thread-worms in the Caecum. No ulceration or congestion in the large bowel which is empty. The small thread worms do not exist in the Rectum.

Abdominal veins very full. Mesenteric Glands swollen soft and very distinct

Case LXXI. Fracture of 1st & 2nd. ribs. Cervical abscess. Empyæma

John Lebie at 20.

Body that of a tall slimly built lad. Rigor mortis present. Skin dry and harsh, coloured brown over abdomen and with endamina. Skin about the neck of a dark purplish colour, immediately above inner margin of left clavicle, the skin is deficient over an area of about the size of a penny, at the central part of this is a small sinus from which a yellowish pus flows. Immediately below this corresponding to the first rib there is another somewhat larger loss of skin & between these two the bridge of skin is thin & presents another sinus. On cutting the skin of the neck a large quantity of blood escapes from the wall of the neck.

see P.M. Report No 1

Case LXXII Ovariotomy. 5 Hours. P.M.

Case LXXIII Cancer of the Stomach Perforation

Francis McCormack Act 33.

Body that of a medium sized well nourished man. Skin anemic. Face slightly emaciated. Panniculus adiposus well developed. Thoray and Abdomen.

~~the intestines are~~ On opening the abdomen the intestines are of a dark red color, here and there covered over with a few flakes of lymph. From the peritoneal cavity ℥XI of fluid were removed the omentum was pushed up and lay beneath the costal cartilages. On separating the transverse colon from the stomach a round perforation is seen in the latter about the size of a sixpence, through which the contents of the stomach had escaped.

Heart. - Pericardium almost universally adherent. No effusion in either pleural sac. Heart large 450 grms. Cavities full of blood and clots. Right ventricle contains numerous dark clots closely adherent to the walls. Tricuspid orifice large admitting four fingers. Pulmonary semi-lunars healthy.

Left ventricle also contains clots dark in color and soft. Orifices and values quite healthy. Walls thick; muscular substance of a healthy red color.

Lungs - Right full in volume, crepitant throughout except at the extreme posterior

border where it is collapsed. Posterior parts of the lung oedematous. Left lung in a similar condition.

Spleen adherent to the diaphragm by its outer surface. On section surface mottled; malpighian bodies distinct, pulp moderately soft.

Kidneys

Capsule detached easily leaving a very anemic organ. On section cortical portion exceedingly pale, the small afferent arteries & malpighian tufts distinct. Pyramids red in color - the apices only a little pale. Vasi recti remarkably distinct. The organ is torn tears with difficulty and is probably both fatty and fibroid. Right Kidney 170 grms.

Liver.

Weight 1950 grms. Exceedingly anemic, lobules entirely bloodless. The larger vessels contain some blood and clots

Stomach.

On opening the stomach a large irregular cancerous mass about 2½ inches in width extends around the pyloric zone but not involving the orifice. In the centre of this cancerous mass and corresponding to the lower and anterior part of the greater curvature there is a round perforation about the size of a sixpence. The margins of the perforation are thin and dark in color. The cancer is hard elevated and at the lesser curvature and at the lesser curvature

softning and breaking down

The rest of the mucous membrane is unaffected, is thin and not very easily torn.
Small intestines,
contain a quantity of dirty dark fluid faces. Mucous membrane looks red, large and small vessels injected. About a foot above the illio caecal valve are numerous ecchymosis Nothing abnormal noticed about the large intestine.

Brain—
Sinuses contain clots. Veins of the pia-mater moderately full. A considerable amount of subarachnoidean fluid escaped on removal. Superficial parts appear quite healthy. Organ reserved for dissection—

231 20/2/77 3 2 hours Pm

LXXIV Pleurisy (right) Pneumonia (left)

Edmund ætat 23. Body that of a slightly built grey man. No rigor mortis. Post-mortem discolouration in dependent parts, and along the superficial veins of the extremities & herpes on lips.

Thorax & abdomen. Panniculus adiposus moderately developed. Muscles of trunk of a healthy red colour. On opening the abdomen much gas escaped. Omentum pushed up. small intestines of a dark grumet colour. In the thorax the right pleural sac was seen to contain a quantity of serous fluid - about 3½ pints - scarcely any in the left.

On opening the pericardium the heart appeared large. and the cavities full. a small amount of fluid in the sac. Heart:

Right auricle distended with dark clots (pale at the upper part) which extend far into the cavæ. Lining membrane stained. Right ventricle full of clots and endocardium of deep red colour. Tricuspid orifice looks admits large; segments thin. Left auricle also distended with clots continuous with those in the veins. In left ventricle partially decolorized coagula, intertwined with the columnæ carneæ Walls of normal thickness, soft & flabby. colour dark red. Lungs. Right in general small, the whole of the lower & middle, with part of the upper lobes collapsed, the pleura of these parts covered over with a thick creamy layer of lymph, numerous flocculi of which extend into the fluid & adjacent to the parietal layer there is also whitish lymph, irregular & shreddy in appearance. Upper lobe of the lung alone is

crepitant at the apex and anterior border, and in section this portion is of a brighter colour, while the remainder of the organ is dark and airless, in a condition of collapse. There is no trace of any pneumonic process. At the dependent portions there is much blood.

Left lung looks larger, and, except the anterior half of the upper lobe, is crepitant, and contains much blood. Section of the upper lobe shows the ant. part in a condition of red hepatization, the air cells filled with distinct granular plugs. The lung tissue in the neighbourhood is congested. The pleura over the solidified part is not at all affected.

Spleen.

looks large, is soft, pulp of a dark red colour.

Kidneys

swollen; capsules detach easily, surfaces mottled, vascular distinct. On section, cortex large, small vessels full. Pyramids dark in colour.

Stomach & intestines not opened, but presented in section look unaffected.

Liver of full size, dark, in section, markedly nutmeg. Gall bladder contains a moderate amount of bile.

LXXV General Tuberculosis. (Meningeal.)

Mammy at 2½ (M.) Body that of a much emaciated child abdomen sunken. cervical glands enlarged, one over ramus of right jaw fluctuates

Brain Dura mater adherent to calvarium & removed with it. On the surface veins of pia are moderately full; a good deal of fluid beneath the arachnoid. Opalescent-white lymph along the longitudinal fissure, especially on the right side, and on separating the hemispheres, the same exists in the region of occipito-parietal fissure on both sides. On the inner surface of the left hemisphere near the fiss. of Rolando, is a patch which thicker than the others, and appears to extend into the substance of the brain, while the pia about it is studded with small tubercles. Over the ~~left~~ frontal convolutions above them are from 8 to 10 tubercles in the pia. Lymph. is also noticed in the parietal lobe of the right side, just above the fissure of Sylvius. At the base the arachnoid is clear, & no lymph is present. The parts about the rt. Sylvian fissure are matted together, & tubercles may be seen about the small arteries. In the left fissure, appearance is normal Nothing noticeable about the upper part of cord or medulla, arach. stretching to cerebellum, from the latter quite clear. On section brain substance ~~soft~~ glistening & moist, not much blood. Ventricles large, & contain clear serum. Walls not very soft, and the fornix & septum are tolerably consistent, being lifted without tearing

Thorax & abdomen. Intestines shrunken and covered over with numerous small dark tubercles from size of pins. shot to peas. They exist also on the parietal layer & in left side form a flattened irregular mass with very dark edges. The glands at root of the mesentery are enormously enlarged, forming a bunch. ~~of~~ the size of the fist of the child. On section they

In the thorax, no fluid in either pleural sac, lungs look full in volume & do not collapse.

Heart small, cavities of right side contain small clots & a little fluid blood. Valves and orifices quite natural. Nr tub. in pericardium

Lungs. Left. a peculiar soft puffy feeling to the touch. Fissure between the lobes only extends about half way when it is joined by another coming from about ⅓ below the apex, the two cutting off a triangular section of the upper lobe. At the lower part of this lobe near the root is an oval caseous mass, firm, encapsuled, & dry. The rest of the organ is uniformly studded over with small miliary tubercles, all of which are grey & translucent. Right lung has same feel & section is stuffed with tubercles of same appearance as the other lung. No caseous masses. Bronchial glands somewhat enlarged, one or two cheesy but firm. Only a few miliary granulations seen in them. One or two tubercles on pleura.

Spleen a little enlarged & tolerably firm; the Malpighian corpuscles white & swollen.

Kidneys. Nothing unusual noticed, no tubercles

Liver. Tissue of pale consistence and good colour. no tubercles

Stomach, not opened.

Intestines

LXXVI Tubercular Meningitis

Ct 5 y/o (M) Body that of an ill nourished, slightly emaciated child right leg shorter than left. from old hip joint disease

Brain

Calvarium thin, dura mater only slightly adherent. sinuses full. Pia mater, bright red in colour, owing to injection of its vessels both small and large. No tubercles or lymph about the vertex & sides, but the arachnoid over many of the sulci is cloudy & granular. At base arach. is clear. Pia somewhat more adherent than usual & parts matted together, but no lymph. Over the right cerebrum presence the same condition & pits and small granulations are seen about the vessel, and a little lymph. Translucent little tubercles occur here & there about the small arteries over the pons & medulla. On the cerebellum near its attachment to the centrum there is a distinct layer of lymph. On section the white substance is moderately firm, does not contain much blood. The ventricles are slightly dilated, walls not so firm as normal & ependyma and septum tear easily. Velum interpositum cloudy & 8-10 small tubercles seen about small vessels in pia mat. Nothing abnormal noticed about other parts of the organ

Thorax and abdomen. Intestines collapsed. small. Nothing Peritoneum smooth. In thorax, lungs retracted, no fluid in pleural sacs. Pericardium, contains a few drachms of clear fluid Heart, about size of child's fist. Cavities right side contain small clots & dark blood. Valves. normal. No segment of aortic semilunar perforated

Lungs. right. crepitant, contains a good deal of blood posteriorly At extreme apex a small caseous spot, size of a small pea, and in the tissue to a distance of 1" about, there are a few dozen.

miliary tubercles. Left. lung crepitant. at apex only there are a few tubercles. none on the pleura.

Spleen. a little enlarged, of average consistence. Malpighian bodies evident

Kidneys. capsules detach easily. surface mottled. Section pyramids injected. Malp. corp. also very distinct

Stomach & Intestines Examined.

No ulceration, or any tubercles in the ileum

Liver. looks large. hepatics veins full.

Right. femur. partially anchylosed with. ischium, and on removal. the head is small, & very roughened, no trace of cartilage.

LXXVII . Pericarditis 18 hrs Pm.

Brooke at 9 ½

24/3/77

LXXVIII Cirrhosis of Liver 18 hrs. P.m.

James Walker.

Body that of an average aged but poorly nourished man. Abdomen considerably distended, Skin in dependant parts about the anus and neck discoloured. On ant. aspect of both legs skin of a dark brown copper color. On right leg is a granulating ulcer.

Thorax and Abdomen

310 ounces of fluid in peritoneal cavity. Position of abdominal viscera appears normal. Border of Liver does not reach the costal margin. Costal Cartilages moderately ossified. Mucous adhesions in left pleural cavity. 3 or 4 ounces of fluid in left pleural sac. 1/2 ounces of fluid slightly colored in Pericardium.

Heart

1/2 ounce of blood fluid escapes from right auricle on flexing

Right Ventricle. ~~Walls thin~~ Empty. Walls flabby. Tricuspid valves a little thickened at margins orifice of full size. Pulmonary valves healthy, one segment fenestrated

Left Ventricle walls of an average thickness. Mitral valves stained and a little thickened at free edges Auricular side of aortic segment contains a thickened patch which is becoming Calcareous

Left Lung

Nearly whole of lower lobe in condition of collapse upper lobe crepitant, Emphysematous particularly at ant. border

Right Lung

very dark in color, lower lobe partially collapsed below. On section very dark and contains a large amount of blood. Upper lobe posteriorly, very dark in color, and edematous. Anterior portion of lung emphysematous.

Spleen

large weighs 880 grammes. Capsule thickened and covered by small fibrine patches. On section organ firm, surface mottled white also mingled with dark red. Vessels and trabeculæ very distinct.

Left Kidney

Organ flattened, Capsule slightly attached on section Cortex and Medulla in normal proportion. Malpighian Corpuscles and small arteries injected. Vasa recta in pyramids injected. Organ is tolerably firm and weighs 163 grammes.

Right Kidney

Contains a good deal of blood. General appearance similar to the Left.

Stomach large Mucous Membrane thick and ~~wrinkled~~ corrugated about the pyloric end on a number of small white spots in the mucous membrane the whole of the membrane is edematous and reddened. Mucous membrane of the ~~duodenum~~ Duodenum also presents these small white ~~spots~~, looking like little lenticular glands. Mucous Membrane of Jejunum thick and tumified Vessels not injected. Peyers patches not enlarged though distinct. Nothing noticed abnormal about the Ileum.

Liver weighs 1580 grammes

Surface uniformly ~~[illegible]~~ lobes of average size shape of the organ retained left lobe wider than it is long this condition exists over whole surface of the organ. In section organ cuts firmly presenting usual appearance of cirrhosed organ

Large intestine Solitary glands evident and darkened Caecum mucous membrane soft, nothing else abnormal

Gall Bladder distended

Portal vein dilated

Bladder contains 2 ounces of urine. blood vessels moderately full Mucous membrane seems easily Pastrate of normal size.

Brain. vessels about base and over cortex tolerably full. A good deal of serous fluid in sub arachnoid space. Organ removed for dissection

Path Report Dep't 24/7/77. 12 hrs P.M.

LXXIX Tuberculous Nephritis

Body that of a short, stout well nourished woman Slight P.M. discolorations. Panniculus adiposus well marked. Linea albicantes distinct and large. Eyes sunken and open.

Abdomen and Thorax.

Belly sunken. Amentum moderately fatty. No fluid in abdominal cavity. Organs bloodless dry and sticky feel, no fluid in pericardiac or pleural sacs.

Heart.

On opening right auricle ℥ii of dark fluid blood escaped. In right ventricle a large decolonged clot, yellowish in color and gelatinous looking. Tricuspid orifice normal size, valves healthy. Pulmonary valve also healthy.

Left ventricle walls of normal thickness. Cotic valves healthy, all segments penetrated.

Right Lung

Middle lobe indistinctly marked only indented by a notch. Lung crepitant throughout, dark red color. Congested posteriorly. Anterior part of the apex, one small caseous mass about the size of a pea. Scattered throughout the lung are a few miliary tubercles, none found in the Pleura.

Left Lung

Crepitant throughout. Apex slightly puckered, little pigmented. At post. part of apex a small cavity about the size of a narrow fat pea, throughout the lung a few Miliary granulations not more than a dozen altogether.

Spleen

a little enlarged. Capsule thin, organ firm and section malpighian Corpuscles very evident, translucent and infiltrated with amyloid matter. Organs Condition known as "Sago Spleen"

Left Kidney

Organ large on section pus tubes, lower end of organ is occupied by 4 or 6 large caseous cysts chiefly in the pyramidal portion, while Cortex surrounding them is thin and atrophied, the remainder of organ numerous small white masses (tubercles) scattered throughout it chiefly in cortex. no amyloid reaction Pelvis and calyces somewhat dilated, on removing Capsule, tiny tubercles are seen on surface, ranging from size of Milium granulation to pea, weight 350 grammes.

Right Kidney.

Small weight 60 grammes, whole organ converted into 6 or 8 cysts, one large one size of walnut at upper end, contains a material not unlike fluid plaster of Paris. a middle cysts contains a clear gelatinous fluid, two (2) cysts at lower end size of marbles contain a soft but not diffluent caseous matter the atrophied cortex forms the outer boundary of these cysts Ureter of this side small but not obstructed

Ureter of the left side full size, not much dilated

Bladder small and contracted, mucous membrane extensively ulcerated and rough. Over greater part of surface muscular fibres are seen.

Ovaries small nothing abnormal about the Uterus
Stomach contains some dirty brownish mucous and
food Membrane soft and turnified, congested at de-
pendant parts.
Intestines Mucous membrane pale the villi conspicuous
show the Amyloid reaction with Iodine the Ileo caeco
& Appendix. Nothing unusual about the large bowel
Liver of average size, substance of pores consistence
seems full, no Amyloid reaction with Iodine
Brain small. Vessels of pia moderately full, nothing
unusual observed about the superficial parts, organs
reserved for dissection
Ellen Blythe P. M.

25/4/77. 244.

LXXX Phthisis 26 hrs P.M.

Agnes Lochhead aet. 22.

Body that of a young delicately built woman, Emaciation extreme, Abdomen sunken, Hip prominent Skin harsh and dry Linea albicantes abundant over abdomen and thighs Hair fair, long and lanky, fingers not clubbed, nails slightly ~~co~~ concaved.

Thorax and Abdomen

Portion of abdominal viscera normal, 3viii of 5ix of fluid in left pleural sac, numerous adhesions at side and apex, more numerous on right side no fluid in opening pericardium, a couple of ounces of clear fluid. Both surfaces smooth.

Heart

Right auricle distended with dark clots decolorized at upper part, long dark clots can be pressed out of both the Cavae.

Right Ventricle Ulnae are also firm coagula which extends into pulmonary artery and auricle valves normal

Left Ventricle Contains a perfectly colorless coagulum which is intimately adherent to the walls. Mitral valves healthy Aortic semilunar also healthy. Muscular substance of normal thickness and pale slight patches of atheroma about commencement of Aorta.

Left Lung

Pleura of lower lobe roughened and covered over with partially organized lymph. Upper lobe. the surface of the pleura, intimately adherent

lower lobe slightly crepitant upper lobe not so. On section upper lobe, especially at post. and ant. parts, is occupied by small communicating cavities, which are filled with pus and breaking down caseous matter: the tissue intervening is pale, traversed by numerous thick trabeculae and the air cells where visible are filled up with little white exudations. Near ant. margin at back part, there is an oval cavity, about the size of a small egg. It is full of a clear, somewhat rosiod jelly-like material. The walls of the cavity are thick dyline. Covered with gelatinous exudations and traversed by Bronchi & vessels, material on walls looks like pearls lymph, no communication with the Bronchi The apex of lung is traversed by numerous strong almost cartilaginous trabeculae, between which is tolerably healthy lung tissue, though solidified. Here and there in lung tissue between caseous matter tubercles are seen as large as pin head to number shot. Lower lobe if this lung is solidified at upper part, contains small tubercle and caseous matter. Pt. the tissue is heavy contains much blood serum and scattered about are single and aggregated tubercles. Bronchial glands are slightly pigmented not cheesy.

Right Lung

Pleura in great part covered over with irregular adhesions, to the touch the lung is slightly crepitant, to the feel made up chiefly of irregular nodules On section the lateral and Ant. part of apex are occupied by two cavities about size of hazelnut, with irregular walls, traversed by remains of vessels and old

Cheesy masses) about the rest of this lobe the tissue is occupied by small cavities Caseous masses and fibroid tissue. The lower lobe is occupied laterally by a cavity the size of an apple. Cavity irregular and injected walls. Anterior to this and extending to lower margin, is a larger one full of dirty purulent matter, the walls occupied by remains of Bronchi and blood vessels. The post. border of lung is riddled with small communicating cavities The Bronchial Glands of this side are size of pigeons eggs. Tumefied, not caseous and contain a few miliary granulations, large ones not pigmented, small ones are Bronchial Mucous Membrane reddened, somewhat swollen, covered with thick viscid secretion.

Larynx. No ulceration of cords or parts. Nor any noticed down the Trachea, small miliary granules tolerably abundant in post. and lateral walls of Pharynx.

Spleen weighs 140 grammes, very much fissured, Moderately firm, vessels full, Malpighian Corpuscles swollen.

Right Kidney weighs 170 grammes, Capsule detaches readily on section Cortex not so swollen, Arteries injected, substance pale, Malpighian tufts faintly visible, Pyramids dark vasa recta injected.

Left Kidney weighs 210 grammes, Capsule detaches readily, having a mottled appearance, general appearance like other organ. Mucous membrane of Pelvis much injected, one or two suspicious looking granulations along the cortex

Stomach contains a quantity of yellowish mucous.

Rougae present, vessels much injected in places, a few ecchymosis

Duodenum Mucous membrane much injected, dark red Common Bile duct pervious

Jejunum Nothing abnormal noticed. At commencement and middle of ileum the vessels and capillaries deeply injected. No ulceration

Large intestines No ulceration, vessels tolerably filled

Liver weighs 1580 grammes. Left lobe much flattened and elongated in antero-posterior direction so that the longitudinal fissure appear in the two lobes. organ rather soft On section presents moderately nutmeg appearance.

Uterus. Is fissured transversely, on cutting, mucous membrane red deeply injected with large and small vessels, muscular substance moderately thick

Ovaries Normal, no corpora lutea. Small pedunculated fibroid mass on right ovary.

Pneumothorax 6/3/77 248

Case LXXXI. Phthisis. Julia Smith ab. 21

Body that of a small fairly well nourished girl

Thorax and abdomen.
On opening abdomen the liver seen to be much pushed down, posterior border corresponding to the lower margin of ribs, anterior border corresponds to the navel. On opening Thorax a large amount of air rushed out of the ~~left pleural sac~~ Right pleural sac, cavity of which is very large, lung not more than half filling it. 18 z of a clear serous fluid removed from this cavity.
Posteriorly the right pleural cavity extended to the 11th rib.
In the left pleural sac 4 z of clear serum.
Lung intimately adherent to upper half.
Right side lung adherent at the whole apex & slightly near the root, being free to the rest of the extent.

Heart. Rt ventricle full of dark gramous clots
Tricuspid and semilunar valves healthy
Rt auricle also contains dark clots
Left ventricle, mitral valves quite healthy
Semilunar valves (aortic) also healthy. Slight patches of atheroma at commencement of aorta.
muscle substance slightly paler than normal.
Walls not hypertrophied.
Left Lung. Upper lobe, not at all crepitant. Lower crepitant at margin, somewhat collapsed below.
On section, upper lobe contains at its outer part a flat irregular cavity, walls of which are crossed by remains of bronchi & vessels. and (over)

Right Lung (Continued) The rest of this lobe, with the greater part of the middle is in a condition of rapid softening, being greyish-white in color, and containing numerous small cavities filled with pus. The lower lobe, is collapsed, contains at its upper and anterior portions softening tubercles, and at the rest of its extent it is free. The perforation does not lead into a definite cavity, but into a rapidly softening portions of lung, infiltrated with pus, and in parts quite diffluent

~~walls of this cavity~~ are dark red in colour.
Towards free margin there is another small cavity, size of a marble, Posterior border of upper half of this lung is riddled with cavities containing a bloody pus. The interspaces between these numerous cavities filled up with caseous masses & bands of fibroid tissue only at the extreme apex, is there a small portion of crepitant lung studded over with miliary tubercles. Lower lobe ~~of this lung~~ slightly crepitant somewhat collapsed & contains here & there spots of pigment. Bronchial glands somewhat swollen, pigmented but not cheesy. Bronchial tubes are congested dark in colour, covered with a frothy mucus.

Right Lung: Upper and middle lobes almost entirely airless except at free border, lower lobe collapsed, but in places still contains a little air, Except the upper lobe above and posteriorly, there are no adhesions; the pleural surface of the lower lobe is covered over, with small patches of lymph; at the upper part of this ~~lung~~ lobe behind, about an inch from the root of the lung, and the same distance from the upper lobe there is a small oval perforation, two lines & 1/2 by two & 1/2 lines, through which low pressure air bubbles. For a couple of lines about the orifice, the surface is pale, beyond that the pleura is injected and covered over with recent lymph. On section of this R. the upper lobe is almost entirely converted into a large cavity (upper lobe, especially behind) Walls thin above and posteriorly; anteriorly traversed by numerous trabeculæ, and there are numerous communications with smaller cavities in this portion of the Lung.

Spleen 133 grammes. Organ soft, on section of a brownish red colour, malpighian corpuscles indistinct, large veins containing a good deal of blood.

Right Kidney 118 grammes. Indistinctly lobulated, capsule removes easily, on section, organ dark red in colour, both cortex & medulla injected, substance of kidney pale

Left Kidney 150 grammes. general characters same as other
Stomach, organ irregular in shape, somewhat constricted
at the middle, contains about ½ pint of dirty
soup like fluid, mucus membane, covered by a
thick closely adherent rouge present.
duodenum contain a quantity of yellowish chyle.
In the Mesentery there are about 11 small
ulcers. In the Cæcum ~~valvula conniventes~~ also
about eight small ulcers. Appendix vermiformis dilated
The M. M. of it extensively ulcerated
Nothing else abnormal.
Liver 1740 ~~grammes~~ 1430 grammes
on section the organ is intensely Hepatic veins
& within the Lobules congested. Organ
extensively fatty. Gall bladder contains small amount
of light yellow bile. Ductus communis Choledochus
pervious — Brain — Vessels of Pia Mater and
very full, a good deal of serous fluid beneath
the Arachnoid. Retro peritineal Glands some-
what enlarged & Pigmented

Case LXXXII Phthisis. Primary. Cancer. Vertebra & Ribs

Body that of Middle aged considerably emaciated man

On opening abdomen, Intestines & Stomach are distended with gas. – Liver, does not extend below margin of rib. Thorax – Left Lung universally adherent. Right Lung also In Pericardium, small quantity of clear fluid. On ~~anterior~~ ant surface of R. Vent. is a large patch of Attrition. ~~on anterior surface~~ – Another exists on anterior surface of L. Vent. near apex R. Auricle much dilated, in the appendix is a firm ante-mortem Coagulum, adherent to its walls, endocardium thickened, In R. Vent. a large ante mortem Coagulum perfectly Colorless. intimately adherent to the walls. Cavity Large. appears dilated – Tricuspid Valves quite thick & gelatinous at free edges, Pulmonary Semi-Lunar healthy Left Vent. empty. Mitral Valves firm & a little thick at edges, Aortic Semi Lunar healthy middle segment fenestrated, Muscle Substance of heart of a dark brown red Color, Nothing abnormal in Left Auricle.

Left Lung – Upper lobe Emphysematous – lower lobe hardly at all Crepitant on Section upper lobe, studded over with tubercles ranging in size from a pea to a pins head. They are firm. whitish in color

& apparently more fibroid than Caseous
Lower lobe is solidified, air cells filled up
with fibrinous plugs, & scattered throughout this
Pneumonic portion are numerous old tubercles
Bronchial glands dont appear enlarged, are
very dark & pigmented, immediately below
root of this lung, are several large Emphysema-
tous bladders, one near free margin, size
of a walnut, looking like a large air cyst
& is in communication with several others
Bronchial Tubes – contain a quantity of dirty
mucous, sub mucous fibroid tissue well
marked. ~~below~~ Right Lung except at
extreme apex & ~~ant~~ free border no part of this lung is
Crepitant. At external part of upper lobe,
laterally, is a large dense mass of Caseous
& pigmented matter, size of an orange, beau-
tifully marbled. On the pleura corresponding to this, there is a puckering
and the two pleural surfaces are here intimately adherent. At the deepest
part of this mass, a large dilated bronchus is seen. Posterior to this ~~mass~~
corresponding to the lower and back part of the upper lobe, the Lung
tissue presents a very peculiar appearance over an area, equal in size
to an orange. It is irregular, soft, and spongy; no definite cavity, but the tissue
above is soaked with pus; while below there is pus mixed with blood.
The tissue is friable, looks not unlike fibrine, but on microscopical examination
seem to be lung tissue infiltrated with cellular elements & rapidly breaking
down. The pleura over it is very thick & fibrous. Nearly the whole of the
lower lobe is in a condition of grey induration, is airless, firm to touch, & a few
caseous masses are scattered through it. Bronchial glands.

Spleen, small weighing 85 grms, on section brownish red in color, vessels & trab. well marked
Left Kidney — Organ firm, capsule detaches readily, on surface small tubercles (?) are seen, on section tissue moderately injected, proportion between Cortex & Medulla natural, weight 165 Grms —— Right Kidney — capsule somewhat more adherent than in left, general appearance same as left — Liver — weight 1470 grms surface grooved by the ribs, scattered over it are numerous white ~~spots~~ masses, ranging in size from a ~~marble~~ walnut to small pea & smaller, ~~some of these~~ Some Surface of most of these smooth & on a level with that of liver, Some of larger have a depressed, umbilicated centre — the largest one occurs on under surface of Left lobe is size of large marble & on section contains much blood in central part, On section of the Organ it is seen that these structures are chiefly superficial, substance of liver itself looks remarkably natural does not appear to be at all fatty. Gall Bladder distended with greenish bile.
Intestines. — No ulceration noticed in small intestine
Stomach. — Mucous membrane thickened, large vessels injected, Pyloric orifice of full size, no ulceration in the ~~Duodenum~~ Cecum or other portions of the Large bowel
Aorta, slightly ather. in thoracic portion

firm & dense in Abdominal part.
Peritoneal glands ~~&~~ not enlarged, nothing abnormal about lower part of rectum.
Bladder appears normal.
Brain of full size. vessels of pia in dependent parts full. arachnoid about the base and behind 4th vent. opaque. No lymph. Small white firm growth size of a pea attached to pia mater on inner under surface of lower convolution of occipital lobe. Similar looking one though smaller on pia upon right crus. Cut the right sylvian fissure & & & there, most of them small about the the vessels, one or two in the left fissure. On section a large round cancerous mass 1½ by 1¼" occupies the superior parietal convolutions on the right side, and extends down the longitudinal fissure for a short distance. It is most trident at the upper surface, where there a slight prominence. On section it is greyish yellow in colour slightly at centre & margins when there appears to be more blood. A small mass size of pea in right. Corp. striatum & another a little larger in centre of left thalamus opticus, both having the same general appearance as the large nodule, and, on examination all are cancerous in structure, the cells being identical in character with those of hereafter described from the vertebra.
Nothing abnormal about the ventricles. a small white firm nodule in velum interpositum. Careful slicing of the organ did not result in the finding of any more masses. Brain substance itself tolerably firm, grey matter of cortex dark. Slight atheroma of the larger vessels at the base

After looking in vain in the usual situations for primary cancer to explain the occurrence of secondary nodules in

liver the Vertebræ & ribs were examined and cancer found in the 1st & ~~5th~~ dorsal vertebræ, & the 2nd. 3rd. 8th & 9th ribs.

Vertebræ. The affection is confined entirely to the second & third, the last most. The bodies are not enlarged, but on stripping of the anterior ligament a soft grayish white fluid oozes out which is rich in cancer cells. The transverse & articular processes & the laminæ are also somewhat affected, being very porous & containing reddish gray juice. In the ant. part of the body of the second the structure is not so loose & porous, but behind in the spinal canal two soft cancerous outgrowths spring from the junction of the body with the laminæ and encroach upon the calibre of the canal, not however compressing the cord or involving the membranes. From the centre of the back part of the 3rd, a small tubercular outgrowth is also seen. The bodies of the 1st & 4th vertebræ are not implicated, the red dish marrow in their cancellæ contains only normal elements.

2nd rib (right) Articular end much swollen, double the size of the 3rd. The articular surface is bare, the cancellæ expanded, and a grayish white fluid exudes from the point to 2" beyond the angle the bone is enlarged and exceedingly friable. As far as the angle the compact tissue has disappeared and the cancerous growth has elevated & infiltrated the periosteum, so that the whole can be readily cut with a knife, cut section presenting greatly widened bone cancellæ filled with a grayish red juice, also some places almost white. The same porosity extends for a short distance beyond the angle becoming less & less as the centre of the rib is reached. Here there is an irregular swelling 1" in length most marked towards the inner surface, & in section it presents the same appearance as the head. Between the head & this growth in the middle normal marrow elements were found.

head of 3rd rib (right) is not much enlarged, & the articular surfaces are free. Between the head and angle it is friable, in section porous & contains a greyish white cancerous juice. The compact tissue is gone but the periosteum remains. Immediately beyond the angle is a spot where the marrow looks healthy & in structure contains the normal elements, with characteristic crystals. Close here is a patch of white tissue, fibrid, with some fat cells. Beyond this for a short distance the marrow is again diseased.

The 8th rib. (left) presents at its middle an elongated swelling 1½" in length, most marked internally. On section at that part is soft & cuts readily, the internal part was made up of dense bone tissue, but cut through with great difficulty. In the soft part and at either end in the cancellæ, cancer cells were abundant.

On 9th rib. (right) there is a still larger swelling of the same character, 2" in length, most developed internally. On both surfaces the growth looked superficial, as if lying upon the bone but on section it was found to extend into, or rather, had grown out from the bone. This piece was not at all hard in the centre but did not present the purity of the cancer at the head of the 2nd or 3rd ribs. Of others which were affected either heads or shafts

7/3/77

LXXXIII Necrosis tibia ac. Pyamia. 26 hrs P.M.

– C. at 13 yr. male.

Body well nourished & of good development Skin & decomposition has begun. Cadaveric odour in room. Abdomen slightly swollen; P.M. discolouration in dependent parts. Abdomen & Thorax.

Intestines distended with gas & dark green in colour, no fluid in peritoneum. Position of viscera normal. In thorax lungs are dark in colour, no adhesions. Slight amount of blood-tinged fluid in pleural sacs.

Pericardium. ℥i of turbid fluid removed. Both visceral & parietal layers covered over with small points of lymph & surfaces roughened.

Heart. soft, flaccid, very dark in colour. Right auricle contains much dark fluid blood & endocardium deeply stained. Rt. ventricle contains fluid blood & a small clot discoloured & entangled in the chordæ tendineæ. In the cones, on the side of the septum, and ¾" below the semilunar valves a purulent deposit the size of a bean was accidentally opened (?) and pus oozed from it. A short distance from it, towards the auricle, there was a superficial loss of substance half the size of a three-penny bit, shallow, & with an irregular base. Whole endocardium deeply stained. Valves quite healthy at the attachments of the chordæ, but are numerous small filaments (?) coagulated adherent. Left ventricle contains small quantity of fluid blood & a little clot. Valves normal. No other purulent spots found in the substance. Traces of atheroma about the sinuses of Valsalva in the Aorta. No clots, only fluid blood in the pulmonary artery.

Lungs of a dark, almost black colour, heavy, only faintly crepitant, and on section much blood & frothy serum exudes. Scattered over both organs are small pin, slightly elevated spots ranging in size pin a pea to marble. They are most abundant in the upper lobes, & altogether 10-12 were counted in each organ. On section some were dark in colour than pin necessaline distinguishing them from the lung tissue. Others had a greyish red appearance, while others again had softened in the centre & formed small abscesses.

Spleen, does not appear enlarged. Exceedingly soft, dark in colour. Small supernumerary organ near hilus (size of a pea)

Kidneys dark & contain a good deal of blood. Uriniferous tubules in the tubules of the pyramids, many of which are filled by them and appear as pale lines on the dark ground.

No abscesses.

Liver, contains a good deal of blood. Tissue soft & easily torn. No pyæmic deposits

Stomach & intestines not examined, but to the feel appear normal. Bladder is healthy.

Left Ankle

Autopsy. 30 hrs after death. By Dr Bell 12/3/27

LXXXIV Cancer of Gall-bladder & Liver

John Orr.

– Mrs Turnbull. æt. 59.

Body that of a well made but spare woman. Skin intensely jaundiced; conjunctiva yellow. Rigor mortis absent.

On opening the abdomen

On opening this abdominal cavity a few ozs of a slightly turbid & sanguineous fluid were removed. The liver is seen to be considerably enlarged and extends fully 3/4" below the margin of the ribs. Projecting from the under surface of the right lobe is an enormously distended gall bladder, which reaches to within 2" of the pubis. The upper surface is free, but to the left side it is attached by dense & cicatricial peritoneal adhesions to the pushed up omentum & stomach. The apex, which is rounded, presents an irregular surface, as if it had been attached, and on the posterior side of the broad ligament, at a point a little to the right of the uterus is a round space, covered with decolourised film, haemorrhagic below, which looks very much as if the gall bladder had been adherent. Behind the uterus it is firmly attached to the transverse colon. Traces of peritonitis, in the form of thin flakes of lymph, exist over the coils of intestines. P. below comes here

Heart and Lungs, quite healthy, a few ounces of fluid in left pleura. Slight atheroma in aorta & aortic segments of mitral

Spleen not enlarged, of a deep dark red colour.

Kidneys, healthy. Nothing abnormal in stomach or intestines. No trace of cancer in any of these organs, nor in the uterus, ovaries, or vertebrae. This 2 comes above An extravasation of blood has taken place into the tissues about, or rather upon the peritoneum in the pelvic cavity especially between the uterus & rectum. The capsules have subsided & left a pale yellow fibrinous layer above, which is firm & quite adherent to the parts about. The haemorrhage is probably of recent date.

~~Stomach appears healthy, there is no thickening or cancerous disease about the Pylorus. Nothing abnormal noticed in the intestines~~

Liver, looks a little larger than normal, and is of a ~~dark~~ greenish colour. Scattered over the surface are a dozen or more elevated tuberous masses, ranging in size from a cherry to a wallnut, white in colour, ~~and~~ the largest of them with depressed ~~at the~~ centres. The anterior portion of the right lobe is separated from the rest of the organ by a shallow groove, the position of which in the body was just below the costal border. The left lobe is flattened and its anterior margin notched. On section the liver substance is deeply bile stained, the lobules are not very distinct. There are only a few of the cancerous nodules in the interior. On opening the distended gall-bladder it is found ~~full of~~ occupied by a large coagulum, the upper part of which, owing to the sinking of the blood corpuscles, is decolourized. Hardly any serum was present, except that contained in the meshes of the clot. 9 or 10 gall stones, about the size of marbles, and with numerous facets were found. At the neck of the bladder ~~orifice of the cystic duct~~, a small irregular mass of cancer projects into the cavity, and completely blocks up the cystic duct. The walls of the bladder are thin, not cancerous, and at the posterior part, ~~that~~ where the transverse colon is attached, there is portion infiltrated with blood. On close inspection it is seen ~~that~~ here ulceration ~~and thinning~~ and destruction of the wall, ~~is beginning~~ has taken place, & there can be no doubt that by this process a vessel has been opened, and the hæmorrhage caused. The glands in the hilum of the liver are enlarged, & cancerous, and compress the hepatic ducts. The portal vein does not appear to be interfered with.

16/3/77 8 hrs PM.

LXXXV Ovarian Tumor – Peritonitis

Catherine Lynam. æ 188.

Body that of a large, somewhat corpulent, woman. Skin of face, neck, & dependant parts generally, of livid red colour. Abdomen much distended, measuring around the umbilicus 42½ inches. In making the preliminary section air escapes from the vessels at the root of the neck & ant. part of thorax. On opening the peritoneal cavity a small quantity of gas escaped from it and a considerable amount also escaped from a small puncture which had been made in the sac during life. About 75 ozs of a turbid sanguinous fluid were removed from the peritoneal cavity. The sac of an ovarian tumor fills up the whole of the front part of the abdomen. The ant. wall is of a dark red colour and scattered over with small extravasations. It is adherent above to the great omentum which is pushed up. On the ant. surface the tumor is attached to the peritoneum a small spot 2" in diameter, to the right of the umbilicus and by another, somewhat larger spot on the left side; and at both these points the membrane is much thickened. At the upper part of the tumor is a large solid mass, attached to the meso-colon. On separating this from its attachment – which is not strong, the parts about are seen to be infiltrated with blood, and on close inspection a large part of the solid mass is seen to be hæmorrhagic. The hæmorrhage has apparently taken place into one of the semi-solid cysts, which, becoming distended, ruptured, permitting the blood to escape into the peritoneal cavity. About 150 ozs of a dirty brownish fluid were removed from the sac. The lining membrane is dark in colour, & to the touch emphysematous, a large portion of the surface is bare the fibrous stroma of the sac being directly exposed; over a considerable part, however, there appears to be a definite membrane, covered with a brownish material. This layer is not uniform and continuous, but strangely irregular, in places quite honeycombed, & presented a most peculiar appearance. The solid mass at the upper part of the tumor is about the size of a child's head & half of it projects into the

sac. To the touch it is tolerably solid, in certain cysts, the cysts being small and filled with a dirty sanguineous pus. Numerous haemorrhages exist in the septa between these cysts. The part of the solid mass external to the sac looks like a large extravasation, but on close inspection it is seen to be not a simple blood clot, but a diffuse infiltration of blood into the tissue of the tumour. Immediately below this and posteriorly are two tolerably firm masses, also cystic, the interior being filled with a thick creamy juice. The whole appearance of the portion is not unlike a malignant growth, inflammation, then an innumerable cylindrical epithelial cells in the pelvis; with a few flattened ones. The tumor springs from the left ovary, by a tolerably narrow pedicle, but the dependent part near the pedicle there are some dilated veins containing clots.

Thorax & Abdomen. No fluid in pleura or in pericardium.

Right auricle distended with dark clots, at upper part decolorized R.V. also contains blood clots. Valves & ostia healthy. Same in left side

Lungs, pretty crepitant throughout, at posterior part a little collapsed.

Kidneys. R. looks small, cortex anemic, Malpighian corpuscles not very marked. Pyramids congested. Left somewhat larger, general appearance the same.

Spleen of orange size, dark brownish red in colour. Malpigh. corp. distinct.

Liver. Left pale, looks fatty, hepatic vessels are full.

Nothing abnormal noticed in stomach or intestines

LXXXVI Pneumonia 30hrs P.M.

Body that of a medium sized man. Slight P.M. discoloration.

Thorax & Abdomen. Stomach much distended with flatus greatest curvature from half an inch below the navel, position of the viscera normal. Liver an inch and a half below the margins of the ribs in the mammary line. On opening thorax left lung does not collapse, and right lung is only slightly collapsed In the anterior mediastinum, over the vessels the tissues are infiltrated w a gelatinous looking fluid. Left lung adherent laterally, posteriorly and at the apex. Right Lung adherent at all the upper part in front by old bands, and also laterally, and behind. Six ounces of fluid in pleural Sac About one ounce of fluid in pericardial Sac

Heart Large, Cavities of right side gorged w blood and clots, which are partly decolorised and intimately adherent w the muscular columns. Clots also extend into the pulmonary artery and into the cava, tricuspid orifice large admitting the tow fingers to the first joint; Valves healthy one segment of pulmonic semilunar fenestrated Left Ventricle, a few clots, and a little blood; muscular walls look thick, mitral valves healthy. aortic semilunar & mitral opaque and thickened at the attached borders Slight atheroma about the commencement of the aorta

Right Lung. Lower lobe posteriorly and laterally is free from adhesions; over the upper lobe, the surfaces of the pleura are adherent partly by old bands, and partly by fresh exudations The upper lobe, is solid throughout. On section, there is an old puckered cicatrix at the apex which involves the

lung tissue, for about an inch from the pleura; the cut surface of the rest of the lobe is greyish-white in color, anemic exceedingly coarse, and bathed by a quantity of clear, serous fluid. at one or two places the bronchi are seen to be plugged with perfectly clear and tenacious fibrin. The large size of the fibrinous plugs filling up the air cells gives to the surface a peculiarly coarse appearance. The lower lobe is congested entirely free from the pneumonia, the middle lobe is very small hardly noticeable from the anterior aspect and situated somewhat to the inside of the upper and middle lobes it is not affected.

Left Lung. Upper lobe crepitant throughout. On section bathed in a large amount of frothy serum, is in a condition of acute edema; towards the anterior margin this condition is not so marked. The lower lobe is uniformly solid and to the exception of the extreme anterior border, quite airless. On section, it is seen to be in condition of red hepatization, surface is of a light red color, bathed in a small amount of serum and has not the same coarse appearance as the other, the larger vessels are full and blood exudes from them. One or two fibrinous plugs noticed in Bronchi and the vessels contain coagula — Weight 1500 Grammes. Right lung Weighs - 1190 Grammes. Bronchial glands slightly tumefied

Left Kidney

Capsule thin, slightly adherent, small cyst size of pea. On section, organ is congested, vessels full in cortex and medulla full — Weighs 190 Grammes

Right Kidney — Weighs 150 Grammes. general appearance similar to that of other organ.

Spleen - Weighs 110 grammes. Organ soft. Structure indistinct. Malpighian corpuscles not very evident

Liver - Weighs 1390 grammes. Very natural appearance larger. Hepatic vessels full. No congestion of the whole the organ is not nutmeg.

Stomach distended & gas -

Intestines - Nothing abnormal noticed -

18/3/77

Diseases of Intestines

Coecum perforation. 32

Ileus 92

Tuberculosis general 26. 8, 75

Meningitis 43, 75; 76

Aneurism 26. 49 Pul. 48, Hep. 53, 87,

Diseases of ~~Female~~ Genital organs

Uterus

Ulcus cervix. 41

Tongue. Cancer. 52

Diabetes. 62

Bones

Fractures 1st & 2nd nk. 71

Cancer. vertebrae 82

Necrosis ac. 83., 96

Lumbar 97

Cerebellum 99

Dear Sir

I am requested by the Comm of publn to ask for a copy of your paper at *your earliest* *convenience*, and also to [illegible] a copy the following resolution.

Resolved that as the Papers read at [illegible] are the prop of the Assocn. the committee request that they do not appear in any of the med journ before they publ in the Transact of the Association.

Black Ward 8

Aug

TEMPERATURE CHART.

DATE.																	
DAY OF FEVER.	18	19	20	21	22	23	24	25	26	27	28	29					
	M.E.	M.E.	M.E.	M.E.	M.E.	M.E.	M.E.	M.E.	M.E.	M.E.	M.E.	M.E.	M.E.	M.E.	M.E.	M.E.	M.E.

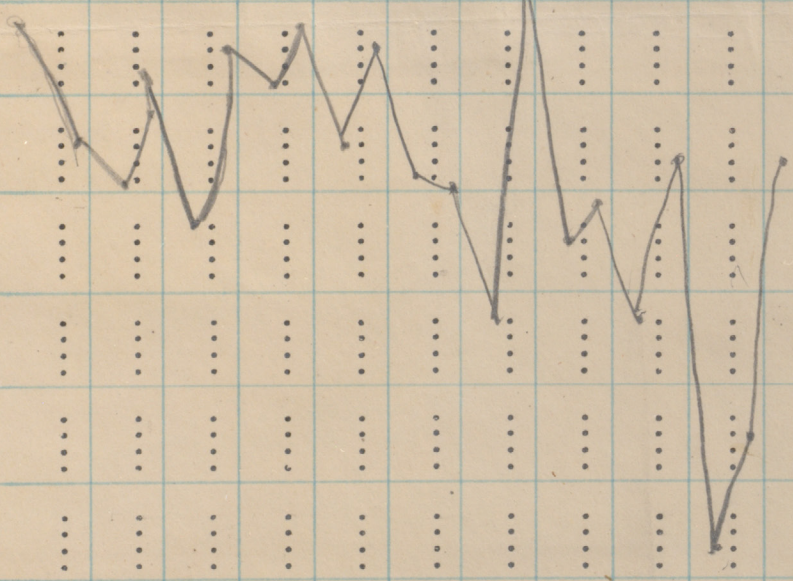

PULSE.	80	90	74														
RESPIRATION.																	
URINE *Oz.*			8	1	1	2	6	1	2	6							
URINE *Sp. Gr.*																	

[illegible] valves healthy except aortic [illegible]

18/3/77

McGill

Case 38. Febroid Phthisis 4
" 39. Heart Disease (?)
" 40 Phthisis 5
" 41 Epithelioma Cervicis Uteri
" 42 Morbus Brightii
" 43 Tubercular Meningitis
" 44 Pleurisy. Pul. apoplexy. Heart Disease
" 45. Cancer of Tongue. - Pycæmia
" 46
" 47 Albuminuria Pregnancy Peritonitis
" 48 Phthisis Hæmoptysis (6)
" 49 Aortic Aneurism (2)
" 50 Aortic Valve Disease
" 51 Pleuro Pneumonia 5
" 52 Cancer of Tongue & Liver
" 53 Aneurism of Hepatic artery Suppuration (?) Hepatitis
54 Tubercular Peritonitis & Pyelitis
55 Primary Cancer of Liver
56. ~~Pneumonia~~ (6) Phthisis
57 Emphysæma
58 Pyelitis
59 Abdom. Tumour - Sp. Peritonitis
60 Pneumonia (6)

61. Progressive Pernicious Anaemia
62 Diabetes. Lobar Pneumonia (7)
63 (4) Phthisis. acute Pleuro-Pneum (8)
64 Abscess of Brain
65 Typhus Fever
66 Brights disease
67 Pleurisy. Fibroid disease of Heart
68 (5) Phthisis
69 Typhus Fever
70 Diphtheria
71 Fract. 1st & 2nd Ribs Empyaema
72 Ovarian Tumour
73 Cancer of Stomach – Perforation
74 Pleuritis dextra, Pneumonia sinistra 9
75 General Tuberculosis
76 Tub. Meningitis
77 Pericarditis, acut.
78 Cirrhosis of Liver
79 Tuberculous Nephritis
80 (6) Phthisis
81 (7) Phthisis Pneumo-thorax. Dermoid Cyst
82 (8) Phthisis. Pneum. Cancer of Vertebra
83 Necrosis tibiae. Pyaemia
84 Cancer of Gall-bladder
85 Ovarian Tumour. Peritonitis
[illegible] P

18/3/77

tic Aneurism. 17 hrs P.M.
dms. Had been a soldier.
cation — Skin over
distribution of
marked about
regions — uniformly
former surfaces
es extremely white.
or isolated patches

ound in right

tion of abdomen &
no adhesions
ide adherent at
l part.
fluid. Patch of
t auricle
ntains a [illegible]
ns clots & appear
entricle full of
agula intimately
adherent to valves & chordae —
Tricuspid orifice large. Valves appear
healthy. Pulmonary semilunar healthy
Nothing abnormal about left auricle
Left ventricle contains a dense decolorized
clot — Walls thick hypertrophied —
Mitral valves healthy except aortic segment



18/3/77

LXXXVII. ~~Pneumonia~~. Aortic Aneurism. 17 hrs PM

— Owen. æt. 62. died 8-10 hours after his adm. Had been a soldier.

Not much Emaciation — Skin over trunk having an irregular distribution of pigment. Discoloration most marked about neck & lateral thoracic regions — uniformly dark on abdomen & anterior & inner surfaces of thighs with irregular patches extremely white. ? of almost general pigmentation or of white patches an leucoderma.

About 1 ounce of fluid found in right tunica vaginalis

Thorax & Abdomen. Position of abdominal viscera normal. Thorax no adhesions on left side — right side adherent at apex, & antero-lateral part.

Pericardium 2 ℥. Clear fluid. Patch of alteration over right auricle

Heart: Right Auricle contains a small qty of dark grumous clots & appears dilated — Right Ventricle full of partially decolorized coagula intimately adherent to valves & chordae — Tricuspid orifice large. Valves appear healthy. Pulmonary semilunar healthy. Nothing abnormal about left auricle. Left ventricle contains a dense decolorized clot — walls thick hypertrophied — Mitral valves healthy. Except aortic segment

Lobi's slight atheromatous. Aortic semi-lunar thick, stiff & atheromatous at bases & corpora — Lumbar & Cerebral parts of segments tolerably natural Mes segments of cerebral —

Aorta — Whole arch dilated — Intima thickened, irregular, rough, & atheromatous — Circumference immediately above valves 3 inches — at the arch opposite vessels 3½ inches — at end of descending portion 3 inches. at end of descending portion there is a saccular aneurism size of a small billiard ball — Projects from the anterolateral part toward the right side — Orifice sharply defined — Upper border straight — Lower & lateral rounded Orifice 1⅛ in. in diameter in axis of aorta 1⅜ in. transversely — Intima of vessel terminates at the orifice of aneurism in a rounded margin — Internal wall of sac made up of a few laminæ & fibrous tissue

Right Lung With exception of middle lobe & anterior margin of upper & lower

Whole lung hepatised. Upper lobe greyish
& Cold, surface bathed with sanguineous
fluid, Lower lobe more reddish —
Surface bathed with a bloody fluid
Pneumonia in several places. Certain fibro-
organisms — Pleura of upper third
part of lungs covered with recent
thin flakes of recently lymph — Lateral
part of upper lobe adhered from
pleuritic adhesions — Bronchial glands
swollen — Pulmonary arteries & veins
filled with long Coagula
Left Lung. Upper lobe divided partially
by a deep fissure extending
inferiorly nearly to the root, anteri-
orly writing 1½ in. of fissure (usual)
N.B. And the fissure in same lobe 3 in.
from apex — On surface of pleura
of upper lobe are numerous small
fibroid thickenings — flat, slightly
projecting, about size of pin's head
Pleura partly lower lobe numerous
ecchymoses — Upper lobe of lung
is crepitant, contains much blood
& froth. Serum — Lower lobe in
middle part is hepatised passing into
into 3rd stage — Bronchial glands
swollen infiltrated with serum but
anywhere caseous, Bronchial

Mucous membrane injected, covered with a quantity of mucus

Spleen 180 grammes. Consistence good — Slightly adherent to diaphragm — On section vessels & trabeculae distinct. Organ contains a good deal of blood

Left Kidney 200 grammes Capsule detached readily Surface smooth — On section organ uniformly reddish tissue looks healthy —

Right Kidney 180 grammes Cyst size of a marrowfat pea in cortex toward upper border — ~~Left Su~~

Left **Suprarenal** Capsule normal size on section natural

Right Suprarenal Capsule — normal & natural looking size

Stomach — Mucous membrane red & congested in dependent parts — Nothing abnormal about it mucous membrane Common bileduct pervious

Intestine Jejunum & Ileum healthy

Pancreas feels firmer & more fibroid than natural. The lobules are unusually distinct

Large **intestine** normal on mucous surface.

Abdominal Aorta thick. intima rough & atheromatous

Liver weight — — —

Surface of left lobe looks slightly granular — right smoother — Capsule thick &

puckered over upper part of free border above gall bladder — This thickening of capsule over nearly whole anterior margin. On section appears healthy. Lobules slightly injected in central part. Portal vessels contain clots —

Brain — 1575 grammes —

On removal some serous fluid escaped — Dura mater natural. Clots in longitudinal sinus — Surface of arachnoid on cortex over some sulci is distinctly ~~somewhat~~ granular — Pacchionian granulations numerous — Sulci wide — Convolutions slightly atrophied — Vessels of pia mater moderately full — Slight atheroma in basilar artery — Nothing abnormal about superficial parts of base. Lateral ventricles full of clear fluid & somewhat dilated — Septum lucidum is membranous. — Nothing abnormal about ventricles — Ganglia at base healthy — Substance of good consistence surface of sections moist.

18/3/77 ~~3.00~~ 2.30

LXXXVIII. Suppuration of Portal Vein. 30 hrs p.m.
Abscesses in Mesentery. Perforation of Appendix &c

General Appearance Body considerably emaciated. Rigor Mortis absent. Hair long dark & on head very Eyes Skin pale & yellow jaundice Pupils of moderate size. Thorax & Abdomen Abdominal cavity Intestines are covered over with flakes of recent lymph and a few matted together, & in some places quite strongly adherent. Pelvic cavity There is a large quantity of thick yellow lymph and the inflammation is much more extensive in the locality. Fully 80 oz of slightly turbid fluid removed In tracing down the intestines to find the cause of the peritonitis ~~was found to~~ be there is nothing unusual met with until ileum is reached Here there are several reddened & injected projecting portions which bulge like small sacs from the wall. The termination of ileum is covered with lymph & very firmly attached. The caecum is also very adherent, & appendix vermiformis

is seen to lie directly on the promontory of sacrum. It is about the length of & same size as under & finger. On carefully removing it the fluid contents escape from an oval perforation on its under side. The Mesentery is enlarged, thickened & contains a large number of suppurating lymph glands. Indeed the whole tissue fluctuates. Some of these fluctuating lymph glands are seen close to the intestine, others, the liver is adherent to the diaphragm by recent lymph.

Thorax. From the left pleural cavity about 5 ½ oz of pus removed. Pus was contained in two pockets, one the size of large orange was isolated, situated immediately at apex. The other corresponded in position to the 3rd & 4th Ribs just beyond their cartilages. This communicated with the pleural cavity which occupied the lower & whole of posterior half of this side. The lung was greatly collapsed & attached along a line 2½ inches in breadth extending from centre of 3rd Rib to apex & 1 Rib below & to

the left of middle along this line the lung was closely adherent. The right lung entirely free from adhesions

Pericardium contains a small quantity of clear fluid. Heart cavities of right side contain blood & glutinous, partly decolorized clots. Valves on both sides healthy a small vegetation exists between two anterior segments of aortic semilunar valves. Muscular substance of good consistence slightly pale from normal

Right Lung & organ crepitant throughout deeply congested posteriorly on a two nodular masses in the apex one of which both recent. On the anterior margin of middle lobe there are numerous small miliary granulations they are not very translucent & do not project. Lung very much engorged. In lower lobe some of these exist on plenum of pressure & along the posterior border at this latter point there are numerous ecchymoses about size of little eruptions of tubercles

Left Lung Slightly crepitant at apex & the
rest of organ is collapsed & airless
& when cut has a good number
of miliary granulations. There are no
coarse tubercles or cancerous masses.
The pleura covering this lung is
from 2 - 3 lines in thickness & in
it & on its under surface are numerous
miliary granulations. Where pericardium
is attached there are much coarser
masses of the whole layer of pleura. Bronchial
glands are not enlarged not cancerous
& contain a few miliary tubercles.
The whole of parietal pleura with
exception of where the lung is
attached is thickened & contains
numerous white masses irregular
in outline but which do not project
above surface

The Vena Azygos dextra is unusually large
& distended with blood almost equal
in size to the Left Vena Cava. The Left is also
very large.

Spleen Weight 330 grammes Consistence good
Surface section of reddish brown Malpighian
corpuscles distinct presents white
mass on application of Iodine they
give turbid reaction

Left Kidney Weight 180 grm Capsule adherent slightly; organ firm On section pale. Larger vessels alone injected organ does not react with Iodine. Cyst about size of cherry towards upper end

Right Kidney Weight 190 organ presents the same character as the other. On more careful application of Iodine there is slight amyloid reaction discovered

Stomach & Duodenum

Stomach. Contains a quantity of dirty greenish matter. Mucous Membrane very soft. Rugae present. Duodenum is intimately adherent in its first part to liver. In its second & third parts ~~are~~ is closely matted together ~~&~~ c̄ a number of suppurating Mesenteric glands(?) Immediately beyond the pylorus the Duodenum is closely adherent to the Gall bladder, the tissues in the neighbourhood being ~~[illegible]~~ matted together ~~are~~ by tolerably firm adhesions, on pressing the Common bile duct a yellowish secretion first exudes to be followed by pure pus. About 1½" from the pylorus towards the upper surface of the first portion of the duodenum pus is seen to exude from a round orifice about the size of a pea, On passing a probe into this it is found to communicate with the enlarged & suppurating portal vein

Jejunum Mucous Membrane dark in Color reacts with Iodine & Amyloid. No ulceration in the Ileum Peyers patches small but look natural The lower end of the Ileum about an inch from the valve is a spot where the wall is thickened & decidedly dark red in Color. The patches noticed appear to be ...

Caecum Mucous membrane very dark in Color no ulceration The Color in its whole length is beyond being dark in color otherwise appears healthy Sigmoid Flexure & Rectum Contain a quantity of yellowish pultaceous feces No ulceration. Appendix vermiformis is thickened, walls swollen & thickened the inner orifice is natural a pin cannot be passed into it from the Caecum nor from the side of the appendix a pin however passed from the latter, enters a small hollow the distance about the 1/16 of inch beneath the Mucous membrane of the Caecum, at its posterior & attached border about 1/2 inches from the Caecum, is a round perforation about 1/32nd of inch in diameter the walls of the orifice are thin & dark in color, but as above stated attached immediately at the promintory of the Caecum, the part about the attachment are firmly adherent by lymph & infiltrated w pus & serum. There is no foreign body or concretion

Liver organ large, firm to the feel, at the same time yielding & elastic. On section the substance cuts firmly, looks glistening & on the application of iodine the intermediate zone of the lobules becomes a Mahogany brown color, the central part & the inter-lobular areas remaining unaffected Over the surface of the organ especially on the Posterior & right borders several small circular swellings are seen; these on section contain pus. ~~The abscesses~~ They are tolerably numerous in these regions & range in size from pins head to marbles many are in communication & each other or are separated by a narrow portion of liver substance On close dissection it is found that these abscesses stand in direct connection &, & indeed, are only suppurating portal veins ~~The~~ portal vein outside the liver for the distance of 2½ inches has thick irregular walls & its internal surface is suppurating passing a probe into its various branches & cutting along it they are found to be full & pust sometimes & a creamy Color at others mixed & bile The branch passing out to the right border of the liver at about an inch from the portal fissure vorders out into 2 large Abscess

*) There is no zone of hyperaemia about the inflamed vessels, but the inner substance beyond the opaque white margin looks natural In branches in which the suppuration is not far advanced the remains of the inflamed, like as a soft stringy mass, can be seen, as if the process was confined rather to the adventitia and sheath. The first an second division of the vein passing to the hinderen right borders contain only pus and the suppurative process has enlarged them greatly; On the bulbus wall the branches of the artery & duct are seen as elevated cords, which sections are patent

on [illegible] to the Right border another towards the posterior chest are full & pass into them are seen opening numerous ~~[illegible]~~ portal branches from which large quantities of a yellowish creamy pus can be squeezed.

Near the upper surface of this lobe is an abscess the size of a walnut, the contents of a greenish yellow pus - in communication with the portal vessel, & from its upper end one or two branches are given off. The posterior border of the organ on section appears riddled with cavities which are merely dilated branches of the Portal vein the lining wall of these suppurating vessels is of a peculiar yellowish white color, tenacious & passes over directly into Liver substance. On almost any section of the Organ these peculiar whitish yellow areas, often of irregular, foliaceous appearance are seen ~~on Extraordinary appearance~~ in the substance - groups of them appear isolated in Liver & not connected with any suppurating area - but on closer inspection it is seen that they always surround small Portal branches, & this probably represents the change in the Liver lobules which takes place immediately before suppuration. These little white masses are from their border sharply defined they look glistening - Wherever suppuration is

taking place these grayish white areas are seen. In the anterior portion of the organ over the gall bladder there is less disease than in other parts, the extreme left border is also unaffected and the transverse fissure. The branches of the hepatic artery look large, and the vessel at its commencement appears almost double the usual size. Along the course of the suppurating portal channels the branches are seen as ~~obliterated~~ cords on the walls. The common bile duct as stated is pervious and a probe can readily be passed into the hepatic duct. The cystic duct is also pervious. At the junction of the cystic & hepatic ducts the submucous tissue is grayish white in colour & the same can be traced extend along the former to the Gall-Bladder. This organ is large somewhat distended and contains about 3ijs of creamy pus not tinged with bile. The mucous membrane is transformed into a thick grayish-white structure, which is here & there congested. At the upper & back part of the opening of the cystic duct there is an irregular sinus leading towards the portal fissure, & along it a probe may be passed for ½" terminating close to the dilated & suppurating branches of the vein, a direct communication with the latter could not be made out, though pus was present. The portal vein outside of the liver is represented by an elongated abscess ~~both~~ walls of which anteriorly are made up of thickened connective tissue, which posteriorly to a large extent, the head of the pancreas, the lobules of which have been laid bare in the suppuration. Immediately where the vessels enter the liver the calibre is relatively diminished. The splenic vein ends abruptly in the wall of the suppurating vessel being closed by a thrombus, the portion behind is much dilated. Unfortunately, in removing the liver, stomach & pancreas together the mesenteric vein was cut away just below the pancreas and no trace could be found of the superior mesenteric vein or the manner, if any, of its communication with the portal. All the parts about the head of the pancreas were closely adherent to each other, and an abscess the size of a walnut was

ended
found near the head of the pancreas
The mesentery felt like a mass of suppurating glands, but on section it was found that the pus was not confined within the capsule of glands but spread diffusely through the folds of the membrane. At the upper part of these still remain some glands, not apparently much enlarged, but throughout the rest of the membrane are thoroughly undermined the pus tracks and all with communicating cavities. In tracing from the intestinal border, some of the veins many are found to lead directly into these suppurating areas, others are shut off by thrombi. On the mesenteric border, close to the artery there is an irregular opening cut across from which pus flows and a probe passed into it passed in different directions, distending it into irregular branches but pus passes all directions and the walls contain projecting trabeculae. Whether or not this is connected with the sup. mesen. vein it is difficult to say. Only one venous opening of any size was found on the border of the mesentery

Lying along the left side of the lower 2" of the abd. aorta & extending down for another 2½ inches at the left side of the ant. iliac and ending in the wall. The rectum is a narrow shut sac full of pus. The walls were thick, dark necrotic & lined by a definite pyogenic membrane. There was no communication with the rectum the walls of which at the point of attachment looked quite healthy. Nor was there any opening at the upper end.

XCIII Typhoid Fever. Perforation 3/4/77

John Erickson Age 29.

Body that of an average sized man. poor muscular development Skin pale dry + harsh & no spots.

Thorax + Abdomen.

On opening the latter cavity the coils of small intestines which are uppermost are of a livid red colour & covered with flakes of lymph, here + there stained with fæcal matter. On tracing down the ileum about 6 in. from the valve a perforation is found.

About 2½ oz of a dirty fluid mixed with faeces removed from the cavity

Thorax — A few adhesions in the left lung posteriorly + a few also on the right. Then was ½ oz fluid in the pericardium.

Heart. Right auricle full of fluid blood + one small clot. Right ventricle also contains fluid blood mixed + pulmonary semilunar valves healthy. Left ventricle nothing abnormal valves quite healthy. Muscular substance looks somewhat paler than natural.

swollen. On removal of the capsule, the surface is a little
rough, and ~~one~~ a few small cysts were noticed in each organ.
Bladder, ovaries & uterus appear healthy
Stomach is distended with gas and contains a quantity
of dirty fluid.
The small intestines as far as the point of incarceration are
of a dark grey colour externally, the walls relaxed, & the volume
of the bowel much increased. They contain a dirty thin fluid & a
considerable quantity of gas. Careful examination of the constricting
band shows that it is connected by both ends to the sigmoid flexure
It is not entirely fibrous but is largely made up of fatty tissue, in fact
appears very like in structure to the glandulae epiploicae attached to the
large bowel near it. At its upper part & near the attachment it is
broad, but the part farthest from the large bowel is exceedingly thin;
the lower portion is thicker. The intestines pass thro' on the side of the ring
next the sigmoid flexure, the lower end of the ileum being uppermost and
nipped about 1½" from the ileo-caecal valve. The mesentery passes thro' on the
right side and at & about the point of constriction is very dark. The diameter of the ring is
rather more than an inch, & the intestine & mesentery are much constricted by it
The Liver appears healthy & is of normal size

Brain. A considerable amount of blood escaped in the re-
moval both from the soft parts & from the interior. The sinuses
full. Veins of pia mater also contain a good deal of blood, espec
of course posteriorly. On section the substance looks healthy, consisten
is good; puncta vasculosa are distinct. Nothing abnormal in the
The optic thalami are united by a broader thick band of grey matter over the 3rd ventr.
ventricles; Parts about the base look natural, basilar artery a
little atheromatous, no exudation or lymph. Careful section of the
every part fails to detect any extravasation or point of disease. Nothing
was found to account for the ext. strabismus

Traumatic Apoplexy

LXXXIX Marcel Lemaire 61.

General Appearance of Body. Body that of a small moderately well nourished Woman. Face much swollen Eyes closed. Over left parietal bone there is a scalp wound 1½ inch in length

Thorax & Abdomen. Position of Abdominal Viscera normal. In the thorax the lungs slightly adherent anteriorly and laterally. 4 ounces of clear fluid in pericardial sac.

Heart. Considerable amount of subpericardial fat along the base and groove.

Right Auricle. Considerably dilated the appendix contains a firm antemortem clot.

Right Ventricle. Cavity looks smaller than natural on dilatation the tricuspid orifice narrowed by a bluish union of the segments it admits only the thumb the chordæ tendineæ shortened the edges of the segments slightly everted and the entire part is in irregular form fibroid growth.

Left Auricle. Also appears large and dilated. Left Ventricle walls thick cavity not enlarged. Muscular substance of a dark red colour. Mitral orifice more constricted, hardly admitting the little finger to first joint the segments of the valve thickened & there are on the ventricular side of Auricular segments a small

patch of vegetation in the other segment on same side is a firm band partly ~~united~~ fibrous
Aorta valve a little thickened slightly. Other at the base and at the upper part of sinus of Valsalva
Aorta very slightly atheromatous.
Left Lung Emphysematous throughout very Emphysematous along the margins On section not much blood Tenacious mucus over from bronchial tube Pigmentation in the lung moderate. Right Lung Small cicatrices dark in colour at the apex organ very Emphysematous on the costal surface of lower lobe there is a firm hard density pigmented nodule about the size of a pea. Bronchial tubes contain a large quantity of tenacious exudation Bronchial ~~tubes~~ Glands densely pigmented.
Spleen. Several old cicatrices along the edge and on the surface. On section surface uniform consistence of organ good veins full. On section of the cicatrices which splenic material is found beneath them. Weight 107 Gramme. Left Kidney Capsule in place but the substance leaving the surface somewhat irregular and puckered. Organ is firm on section. The proportion between cortex and medulla both natural Weight 110 Grammes Right Kidney. Capsule also slightly adherent general appearance of organ corresponds to the other.
Stomach. Small ridges present mucous membrane looks pretty healthy. At the pyloric end are two papillary growths each about ½ inch in length and attached by tolerably large bases which is somewhat constricted the apices of them are reddened and

injected. The pericardium appears healthy. Small intestines look healthy. Organs pertaining to digestive appear healthy, nothing abnormal in large intestines

Liver. small anterior edge pinched and irregular On section the intralobular vessels congested and is in the state called nutmeg.

Uterus & Ovaries. both ovaries in a condition of cystic disease the cysts about the size of walnuts and filled with a clear fluid. Uterus large mucous membrane hemorrhagic swollen and very vascular

Brain. on lifting the dura mater over the right hemisphere is a large coagulum over the whole surface of the hemisphere and extending to the base on the outside of the temporo sphenoidal lobe there is a effused area composed of blood and brain matter the vessels are most marked on the upper convolution at which place it looks almost like a laceration. towards the posterior part of the convolution there is more blood.

the left hemisphere the convolutions are separated by wide and deep sulci over the frontal and some of the parietal convolutions on the R. & Hemis from the post parietal convolution there is a small extravasation of blood about the size of a pea the lateral and posterior parts of this hemisphere there is a distinct flattening of the convolutions the brain substance at the point extravasation more firmly than at

All other parts: Lateral ventricles empty choroid plexuses pale Convexity soft. Substance of the brain of good consistence nothing abnormal about the ganglia at the base ~~vessels~~ also the vessels.

XC

Pneumonia

29/3/77

Thos Pm.

John Mc Gary. æt. 48

Body that of a moderately well built man fairly nourished. Rigor mortis present. Skin pale, covered with freckles. Face thin. Eyes open. Pupil of moderate size

Thorax & Abdomen Position of abd. viscera normal, Colon much bile-stained. In thorax the tissues of ant. mediast. are infiltrated with a glutinous serum. Right lung free in front and does not collapse a few adhesions lat. & posterior & at apex. Left lung does not collapse, is firm to touch above and is closely attached to rib. Pericardium contains 3ii of clear fluid

Heart. Rt auricle distended with blood & clot. Rt. V. also contains firm clots which extend into the pulmonary artery and auricle. 3v of fat escaped on removal of heart. Tricuspid orifice dilated admitting 4 fingers; free margins of the valve a little thickened. L. Ven. also contains partially decolorized clot. L. ventricle walls appear thicker than normal. Aortic semi-lunar valves healthy, one seg. fenestrated. Sinuses of Valsalva large. Aorta slightly atheromatous at commencement.

Right Lung Ant. border emphysematous. On section the surface is dotted with a great. of clear, frothy serum. The tissue is everywhere crepitant & posteriorly congested, at low. margin of lower lobe there are patches of collapse some of which have inflamed — lobular pneumonia. Br. glands somewhat swollen, & intensely pigmented, Br. tubes filled with a frothy serous exudation. Pulmonary veins contain coagula. Weight 710 grms.

Left Lung, with the exception of the extreme ant. border, the whole of the upper lobe is firm, solid & airless, in a condition of grey hepatization. The pleural surface is covered over with a tolerably thick & very firm pleuritic membrane. The cut section is greyish white in colour, somewhat mottled below, & presents all the characters of pneumonia spreading over

into the 3rd stage. In the anterior part the process is more advanced & the cut surface is bathed with a purulent fluid. The upper part of the lower lobe is in a state of red hepat. The rest of the lobe is greatly congested & oedematous, & along the lower posterior margin are several spots of collapse.

8/4/77 286

XCI Kyphosis. Bronchitis. Pul. collapse 1½ P.M.

M. Gallagher. æt 12.

No rigor mortis. Face cyanotic, ears especially so. Arms & hands also. ~~[illegible]~~ P.M. discolor in dependent parts. Knees reddened skin abraded, elbows in same condit. Child has been in habit of resting upon them. Legs much swollen. Vulva also oedematous. Thorax projects greatly. Abdomen protuberant. Spine much curved in the whole dorsal region, convexity behind. Shoulders much elevated.

On opening abdomen 28 oz. clear fluid removed. Intestines dark red. Position of viscera normal. A few slight adhesions between layers of Periton: over several organs especially liver & spleen, &

Thorax. Exceedingly contracted in vertical direction. Ant-post. diam. increas. Left lung adherent laterally by old bands

Right lung adherent at apex & sides by more recent gelatinous adhesions

<u>Heart.</u> Right auricle large – Appendix much dilated. Orifice of the Coronary vein large. Endocardium opaque, especially over the Fossa Ovalis. The cavity contains much blood.

Right Ventricle very large. Looking ½ as large again as the left. On opening the cavity appears dilated. The inner surface of walls ~~[illegible]~~ by large & hypertrophied Columnae Carneae. Tricuspid orifice. appear considerably dilated. The valves are slightly gelatinous at their free edges.

The Pulmonary semilunar valve healthy. Left auricle nothing abnormal about this cavity but it is ~~[illegible]~~ very small. About its base beneath pericardium are several small extravasations of blood. Left ventricle small, walls appear of moderate thickness. The contrast between the Columnae Carneae in this cavity and those in the right ~~are~~ is very striking. ~~Mitral~~ Valves healthy

Aortic semilunar also appear healthy

Right Lung. upper lobe - contains very little air but portion removed still float. The lobules are distinct the tissue is firmer than ~~normal~~ being in a condition of splenization. The lower and middle lobes contain more air. and much blood and serum

Left Lung. upper lobe. crepitant. surface section contains much blood. Almost the whole of the lower lobe is in a condition of collapse. The lobules well-marked. tissue dark in colour. on the cut surface, and ~~from~~ the cut surface much clear serum exudes.

Trachea & Bronchial Tubes on opening the former it was found full of tenacious blood stained mucous. This extends into the bronchial tubes to their ultimate distribution. On removal of the mucous the bronchial membrane is seen to be reddened in some places with ecchymoses. The tubes appear to be somewhat dilated. The glands of bronchi are not enlarged on section contain much serum.

Left Kidney. uniform firm. Capsule detaches readily on section cortex is anaemic except the Malpighian Corpuscles which are well marked. In the Pyramids Vasa recta are injected.

Right Kidney somewhat smaller and presents same appearance

Spleen. irregular in outline. Anterior border very fissured Capsule adherent to the Diaphragm. On section pulp is firm. dark red colour - Malpighian Corpuscles indistinct - Trabeculae clear. and vessels are well marked

Stomach contains a dirty black material. Mucous membrane soft. and deeply injected along the curve and in dependent parts

Intestines Mucous membrane of Jejunum is reddened and injected especially along the free edges of the valvulae Conniventes. numerous small ecchymoses over all the upper part of ilium

Peyers are not enlarged. In Caecum there are scattered ecchymoses pretty distributed. The first part of Duodenum about 1½ inch from Pylorus there is a distinct ulcer upon the posterior wall lying between two valvulae conniventes about the size of a 10c piece irregular in outline. On pressing the Gall bladder bile flows from the Papilla Biliaria.

The Liver:- small - firm to the touch. The central veins of lobules are injected and the cells contain a yellowish pigment matter. In the peripheral part of lobules the tissue is translucent and on iodine gives a faint dark brown colour c̄ Iodine.

Peritoneum: in various parts about uterus are inflamed c̄ adhesions.

Brain 1425 grammes. Veins full & injected c̄ in the dependent parts.

XCII Ileus. — Incarceration. 3/4/77. 13 hrs. P.M.

Mrs Anderson. æt. 50. Body that of a well made and healthy looking woman. Skin of face & neck purplish red, & same colour in dependent parts. Discharge of ill-smelling fluid oozes from the mouth & nostrils. Abdomen only slightly distended. Rigor mortis slightly marked. Thorax & Abdomen.

On opening the peritoneal cavity a small quantity of bloody fluid is found, chiefly in the pelvis. The coils of small intestines which are in apparent present a slate grey colour, are relaxed, their surfaces smooth, & present no sign of inflammation. On tracking them down towards the cæcum it is found that the lower 20-24" of the ileum has passed beneath a peritoneal band stretching across from the sigmoid flexure to the mesentery (2) and has become strangulated. The portion so incarcerated lies in the pelvis is very dark in colour, in places almost black, looking as if the necrosis of the part was beginning.

In the thorax, the position of the viscera was normal. The lungs were not adherent, only a few thin bands posteriorly

Pericardium contains a small quantity of clear fluid. a good deal of fat beneath the visceral layer

Heart, of average size. Cavities on right side contain much blood, less in the left chambers. Tricuspid and pulmonary semilunar valves healthy, Rotting abnormal in left ventricle One small round localized swelling on edge of aortic segment of mitral & slight atheroma in body of the valve & where it is attached to aortic ring. Coronary arteries rigid and calcareous

Lungs are healthy, crepitant throughout.

Spleen of average size, soft; pulp friable, & dark in colour.

Kidneys, contain much blood, substance coarse. & cortex looks

Right Lung.— crepitant throughout & contains very little pigment. Posteriorly the lung contains much blood scattered throughout the lung are several small patches of apoplexy.

Left Lung.— Crepitant. Beneath the pleura in lateral region in the upper lobe is an extensive extravasation of blood & beneath this in the substance of the organ are a few spots of apoplexy.

Spleen.— weighs 395 Grammes On section dark red in colour soft. Malpighian corpuscles distinct but not much swollen.

Right Kidney. 160 Grammes. On section Cortex moderately pale. Larger vessels contain blood. Capsule detaches readily. Left Kidney presents the same character as the other.

Stomach. Mucous membrane is dependant in [illegible] parts. soft. tears easily.

Liver. flattened very much. on section. surface is uniform [illegible] friable.

Brain. 1330 grammes — Membranes appear healthy.

Intestines — Nothing abnormal noticed apart the Ileum.
In the Ileum as the lower part of the bowel is approached there are several ulcers. Most abundant at the lower part of the bowel close to the valve. Most of these are small & round. Not elevated & present adhering to them yellowish stained sloughs. About 4 inch from the valve one of them have perforated. About the size of a shilling and about the edges of perforation at two places - are thick yellowish sloughs. The muscular encyptence of the perforation is a muscular coat of intestine which has taken part of ulceration. In some of them ulcers the slough are only just beginning to separate loosely from the surface. Close to the valve itself the ulcers are thickly set, from most the slough have separated leaving punched out ulcers. The coats of which are formed by the muscular coat of the wall. The largest of these ulcers about size of 1/2 dollar. There is no ulceration of caecum. The coil of appendix is faintly affected

4/4/77

XCIV Calculus vesicæ

2 hrs PM.

J. Griffin ætat 79.

Body much emaciated. Rigor mortis has disappeared. Skin dry & harsh.

Thorax and Abdomen. Small intestines of a slate grey colour, and distended with gas. About 8 inches from the pylorus ~~two~~ coils a piece of the gut is bent upon itself and the peritoneal surfaces firmly adherent by old bands. About a foot from the valvula Bauhini the ileum is much curled upon itself and the coils closely united by old adhesions.

Similar adhesions are met with between the cæcum and beginning of the ascending colon, and in several places there are fibrous bands stretching across from one part to another. The ~~int~~ abdominal ring admits the thumb, which can be passed through it. (We had time had a strangulated hernia reduced. There was no history of any attack of peritonitis). Portion of thorax removed. In the right pleura there were about 8 ozs of a turbid purulent looking fluid and the pleural layer covering the lower part of the lung was covered over with a thick creamy layer of exudation. Nothing abnormal in pericardium heart. Cavities on right side contain dark clots. Mitral and pulmonary semilunar valves healthy. Mitral valves a little thickened and atheromatous at base. Aortic valves opaque & thicker than normal. Coronary arteries rigid and atheromatous. Muscle of a dark brownish red colour.

Aorta is somewhat dilated and calcareous plates are scattered in the intima. Orifices of three have rough projecting points. In the thoracic and abd. part. similar plates exist. one a very large one.

portion dark in color. & swollen, & covered with purulent material from the anterior part of the membranous portion a wide false passage proceeds from the upper part for nearly an inch. It presents several diverticula. Nothing abnormal noticed about the stomach or intestines. The large bowel contains a large amount of solid feces.

The liver smaller than natural, owing to the atrophy of the left lobe, which appears to terminate in a small portion 2" in diameter 1" in thickness & united to the main portion by a firm tendinous band, in which are seen numerous vessels. The capsule of the right lobe is also a little thickened. The liver substance is soft, not cirrhotic. Gall bladder full. No gall stones

Lungs, not adherent, crepitant throughout; moderately pigment; slightly emphysematous about ant. free borders. The apex of the left is covered with a thin partly osseous partly cartilaginous plate, about 3 lines in thickness

Spleen, of average size, dark reddish brown on section.

Kidneys appear of normal size, are soft and flabby. The right one on section presents a pale cortex in which the Malpighian corpuscles can be distinctly seen as small red dots. The pyramids are darker in colour, somewhat congested, and the apices of gland portions embraced by the calyces are in many places eroded & covered with greyish, closely adherent matter. The loss of substance is neither deep nor extensive. The pelvis with its prolongations is considerably dilated, the mucous membrane dark red in colour, (the vessels full) and covered with a dirty purulent material, in which small excoriations may be seen. Left kidney in the same condition; a calculus half the size of a pea found in one calyx. Ureters are moderately dilated, the right more than the left. Mucous membrane, doubtless inflamed, is soft. In the contained fluid particles of calculi occur.

Bladder contains about an ounce of turbid fluid, and nearly a couple of drachms of crushed calculus. The m.m. is dark in colour; in places eroded, but not deeply. Around the orifice of the urethra there are a number of irregular projections, covered by the m.m. The largest is behind, looking like a projection of the med. lobe of the prostate. The ant. one is not so prominent, is irregul. divided by a small fissure & is separated on the left from the former by a fissure. On the right there is a small pedunculated portion a little larger than a pea, freely moveable, and which fits directly over the urethr. orifice, being displaced in the passage of the catheter. The muscular walls of the organ are somewhat hypertrophied, and numerous trabeculae mark the inner surface. The Prostate is of medium size, the orifices of the ducts large & occupied by numerous calculi, the largest the size of a pea, they were brownish red in colour. Mucous memb. of prostatic

XCV Pneumonia 23 hours after death

Alfred Petroff aet 31

Body that of a muscular well nourished man, medium height. Rigor mortis well marked considerable post mortem discoloration over posterior parts of the body, and patches on the ant. part. a white depressed cicatrix on front of left thigh, and one also on left shin.

Abdominal & Thoracic viscera normal in position. Pericardium contains an ounce of clear fluid. At Right Pleura adhesions at post. part & outer surface of the upper lobe, these adhesions are firm & old. Left Pleura recent adhesions, easily broken down, over the whole surface of the lower lobe. Contains 1½ oz bloody serum.

Heart. 443 grammes. Large & soft. Right Auricle contains 3 oz. of dark clot. decolorised clot in the aorta. Partially decolorised clot in the Right Vent. & studding into the pulm. artery. Pul. Semilunar valves healthy. Tricuspid orifice admits 3 fingers as far as the second joint. Mitral admits points of 3 fingers Valves of both orifices healthy. Aortic S.L. valves & aorta healthy. Right Lung crepitant throughout with the exception of the base where it is only slightly so. weighs 660 grammes on section a quantity of bloody serum & air

Left Lung. 1539 grammes, whole cavum of which is covered by a layer of lymph, on section it is grayish red in color. Small white granules in the pulmonary vesicles well marked
Spleen normal 140 grammes.
Liver 2140 grammes. Very firm to the feel, pale in color, on section a considerable quantity of blood exudes, vessels on surface distinct & have numerous ecchymoses along their course, on section central vessel of the lobules are very distinct
Kidneys. L. K. 200 grammes. Very full of blood. Malph. tuft & vasa rectae of the pyramids intensely injected. Right kidney weight & characters the same
Brain. Longitudinal sinus full of blood partly coagulated, considerable serum escaped on cutting the dura mater (about 3ii — 3iii). Vessels on surface moderately full of blood. Some serum beneath the pia mater, Puncta vascul well marked. Choroid plexus congested —
Substance healthy —

Acute Necrosis of Femur. Pyæmia

XCVI

16/4/77

John Cagle æt 30.

13½ hours post mortem.

General appearance.

Body that of a well built muscular man. Rigor mortis present. Skin of dependent parts livid & decolorised. Dark livid patches also exist on the arms hand & face. Scattered over the skin of the trunk & upper extremities, are numerous flattened pustules. Some of these are small vesicular in character with reddened bases. The majority of them are elevated, flattened and contain a sero-purulent fluid. The largest of them is of a diameter 1/2 an inch by 1/4 th. The basis of some of them are hæmorrhagic. Beneath the skin of the arms, small and large tuberous elevations are seen, and can be plainly felt, and plainly seen, in slightly elevated knots. Several of these are also seen in the leg; on puncturing them, pus exudes. In the Left Calf several nodules are felt; on section these are found to be localized depots of pus in the substance of the muscles. Several similar deposits are found in other muscles. The long internal Saphenous vein of the left leg, is plugged about the middle with a thrombus; it could be felt externally as a firm cord. On removal and slitting it up, the upper part was free, though much contracted. At a pt. or' to the middle of the thigh the vein presents an oval swelling: internally this is seen to be a decolorised soft mass, occupying the calibre of the vessel: it is soft and closely adherent to the intima:

Thorax & Abdomen:

Position of abdominal viscera normal: stomach distended with gas. the Pericardium contains about 4 ozs of clear fluid, no adhesions on either side: Heart of over size, on removing it a considerable quantity of dark fluid blood escaped; the visceral layer of the pericardium over the R. Auricle is slightly roughened: R. Auricle contains some fluid blood and a partially decolorised clot, which is continuous with a clot in the R. ventricle: R. V appears healthy, no sign of endocarditis. L. ventricle rigor-mortis present, walls in consequence very thick; mitral valve quite healthy, aortic semi-lunar valves also quite healthy: slight patch of atheroma at the base of aortic segment of mitral.

Lungs: R. Lung: numerous firm nodules can be felt over the surface of the lobes, especially the lower lobe; they are elevated, the larger ones flat, the smaller more pointed: the largest of them about the size of a marble; the smallest the size of a pea. On section, they present a white granular surface, which in the larger nodules intermingles with injected and hemmorrhagic portions. The lung tissue itself retains a good deal of blood especially in the dependant part. The bronchi-tubes contain a quantity of dark mucous: the R. Lung innumerable nodules exist in this lung (similar); chiefly in the lower lobe and superficial parts: the major of these on section are white in color and firm; in one or two of the larger ones there are signs of commencing suppuration: the margins of these masses are congested and frequently hemorrhagic: Bronchial glands, dark in color and deeply congested: "Spleen 170 grms, consistence good, organ contains large amt of blood "the Malphig corpuscles can be plainly seen: some of the superficial parts of the organ are unusually firm and much congested.

Kidneys: R. K. 170 grams: capsule detaches with slight diff'; on section the Cortex is somewhat pale, some of the small arteries

alone injected. L. Kidney 190 grams appearance same of Right; texture somewhat coarse, no trace of any pyaemic-deposits
Stomach, contains a quantity of milky fluid, the larger veins are full; about the Cardiac end, the m. m is duply congested and ecchy

Intestines.

Nothing abnormal in the Jejunum, it contains some yellow faeces: in the Ileum, Peyer's patches are distinct, the mucous membrane appears quite healthy. Large intest contains a quantity of yell' colored faeces, which appear normal.

Liver.

Weight 2170 grams. organ appears of full size; and from its vessels a considerable quantity of thin blood can be squeezed. The lobules are indistinct the finish' portions somewhat injected. Gall-bladder contains a quantity of dark and somewhat inspissated gall

Brain.

A good deal of serum and blood escaped on removal of the organ. on Lupus exam' organ looks normal; it was resent for dissection.

Left Knee.

A drainage tube passes thro' the tissues of the thigh immediately over the Patella, the whole of the muscles and their sheaths are infiltrated with pus which extends as far as up' border of lower third of thigh. The muscles immediately beneath this part of the thigh are also infiltrated. The Pus does not appear to extend below the Knee joint; nor are there any signs of inflam' or pus in the cavity of the joint itself. The posterior part of the lower third there are numerous abscesses close to the periosteum. Periosteum. removed about the lower end of the Femur and especially in the neighb' of the inner Condyle, this membrane is raised and there is pus beneath it. The membrane is vascular, and at the inner and back part easily seperated. The bone corr' to these parts is roughened

and in places covered with a dirty greyish exudation.
On the anterior part the bone is also rough & numerous elongated narrow channels are exposed on this surface.

97. see Path Report.
I p 94

Pneumonia.

XXCVIII Elizebeth Summers Died April 19/79

Body that of an elderly well built woman. rigor mobis present, slight post madem discoloration, face considerably emaciated eyes sunken & opened V
Thorax & Abdomen.

Position of Abd. Viscera normal. Liver projects 1½in below the Costal border in the mammary line, & at this part the upper surface is white & fibrile.

Right Lung adherent posteriorally & at apex; left adherent in front by old bands; post & by recent easily separated adhesions. Pericardium contains ½ oz of clear fluid a few ecchy. on the parietal layer, a few ecchy. in the right auricle.

Heart:-

Right Auricle distended with Blood & a firm antimortem clot Rgt. Ven. contains a firm decolorized clot. adherent to the chordae Tendineae Tricuspid Orifice a little larger than usual. Valves healthy. Pulmonary Semilunar also healthy. Lft. Vent. firmly Contracted & contains a decolorized clot; Mitral valves slightly atheromatous at base, Aortic valves somewhat opaque & very firm at attached border. Heart Muscle dark brown color, ascending Aorta slightly Atheromatous

Left Lung:- wgt 420 gms.

Organ slightly crepitant, at the apex there are several old fibroid &c. & one calcareous nodule. in lower lobe Post. there are one or two patches of Pneumonia over these portions the Pleura is opaque & thickened Several small ecchymosis on the Pleura especially that between the two lobes

at lower & Ant. border of lower lobe. The Bronchial glands are dark & much pigmented.

Right Lung:- wgt 1200 grammes

With the exception of Ant: Border & the extreme apex the whole of this lung is in a condition of red hepatization. at the apex the disease is more recent than at the base, the lung tissue being redder & more vascular. the lower lobe the disease is passing on to the third stage the cut surface is bathed with a slightly purulent fluid, the pleural surface over lower lobe is covered with a thick dense membrane which is easily separated the Bronchial glands are pigmented & somewhat swollen the Bronchial tube in affected portion of lung are in many places the mucous membrane is intensely congested but does not appear swollen pulmonary vein contain Coagula

Right Kidney:- wgt 120 grms.

Capsule detaches with difficulty bringing portions of substance with it, surface slightly granular here & there as size. on section the substance is pale in the Cortex the Malp. tufts are injected. the organ cuts firmly

Left Kidney wgt 95 grms.

Capsule detaches more readily Vessels as well marked. general condition of organ same.

organ Spleen:- wgt 80 grms.

organ small much fissured, on section substance brownish red. Mal. Crp. indistinct.

Stomach:-

Stomach contains about ½ pint of greenish brown fluid. Mucous membrane soft, easily torn, deeply injected & ecchymotic at cardiac end Duodenum appears healthy, common bile duct is pervious

Intestines:-

Nothing abnormal noticed in the Jejunum nor Ileum, the lower part of latter is perhaps somewhat congested. no trace of any parasites in the small intestines.

Large Intestines contain a small amount of feces Mucous Mem. of Cecum & ascending Colon appears quite healthy. Ileum small Peritoneum over it covered with ecchy. Ovaries small & very cicatricial, Bladder distended with Urine, Muscular trabeculae well marked

Liver:- wgt 1340 grms.

Capsule over the Ant: part: thick, hard Calcareous nodule the size of a pea on the upper surface. on section organ contains much blood, the central vein globules are injected. Gall Bladder contains a few drachms

Brain:-

Large veins of Pia Mater full, on section consistence of organ is good, ventricles appear healthy, vessels about the base somewhat Atheromatous

On cutting the muscles of Thorax to open this cavity, they were seen to be densely crowded with encapsuled Trichinæ, these parasites are found throughout the whole of the voluntary muscles being most abundant near their tendinous attachments very numerous on near the Diaphragm & in its pillars, none existed in the muscular substance of the Heart.

Case XCIX Convulsions

40 hrs. P.M.

X.Z. at 2 weeks, a tolerably well nourished "Brt." Infant. Thorax & Abdomen. Position of abd. viscera normal. no. pus in intercostal tissues in thorax, lungs collapse naturally & are of good colour.

Pericardium contains a few drachms of fluid. Heart of normal size right cavities contained a small deal of blood, partially coagulated. The foramen ovale was not quite closed, an elliptical prime being visible on the right side on looking into the rt. auricle.

Lungs. Right is collapsed over a considerable area behind, and appear to be in a state of commencing inflammation, similar patches exist in the left lung posteriorly. Antero-lateral part of the lung look healthy. Nothing abnormal about the spleen, liver, or gastro intestinal organs. The kidneys are of a dark blue colour & on section appear in places almost haemorrhagic, especially about the cortical part. In these spots they are infiltrated with blood & look quite apoplectic [illegible]

C Epilepsy. Johns P. H.

Jno Carney. Aet 43.

Body that of a large muscular man. Rigor mortis present. Slight P.M. lividity in dependent parts

Thorax & abdomen. On abdominal cavity omentum was seen drawn down and to the left, being very dense. On tracing it down it was found to pass thro' the ring into the tunica vaginalis, to the inner wall of which it was firmly attached. The part in the sac is very fatty, covered over with irregular warts and fine nodules. The position of the other viscera appears normal. On the thorax the lungs are free from adhesions, nothing in either side, a few drachms of fluid in the pericardial sac. On the visceral layer there is a small patch of attrition over R. V. and a few small fibroid patches exist about the great vessels. Right auricle large size. Right ventricle also appears large, walls stained, tricuspid ring normal in size. Pul. S. L. valves quite healthy, over the ant-segment decidedly larger than the others. Left auricle appears normal Left ventricle walls are also stained. Mitral valves quite healthy Aortic S. L. valves also healthy, one segment much fenestrated Heart substance very pale & looks fatty.

Lungs. Left a few small cicatrices beneath the visceral layer of the pleura posteriorly. In the fissure between the two lobes there is a long narrow shred of lymph. The apex is emphysematous. On section there is an old puckered cicatrix at the apex at the centre of which is an old caseous firmly encapsuled nodule. In the periphery of this along the fibrous band there are small bodies looking like miliary tubercles. Post. lobe on section is found to contain much blood & frothy serum. looks as if there was a condition of hypostatic congestion
Right Lung there is a small caseous mass half the size of a pea at the lower & lateral part of the ant. lobe. The tissue about this in the radius of an inch is traversed by fibrous bands and contains numerous tubercles. a couple of inches below this there is another similar patch with a larger caseous centre. A third also exists at the inner part of the apex itself. another small patch exists at the upper & lateral border of the lower lobe. In this and the caseous mass is large but the secondary miliary tubercles are few in number. The lung tissue is heavy, contains much blood and serum esp. in the dependent parts There are no miliary granulations other than those mentioned, to be found. The bronchial tubes contain much frothy mucus and the membrane looks reddened and congested
(over)

The bronchial glands are pigmented, not enlarged, not caseous and contain no miliary tubercles. Portions from the lower border of the right lung sink in water. Spleen 15.7 grammes. Pulp soft brownish red in color and contains moderate amount of blood. Capsule is slightly fibroid. Right kidney capsule detaches with difficulty leaving surface irregularly congested. On section tissue soft & flabby. Vessels at base of pyramids much congested & stained. P. M. imbibition. Left kidney not examined nearly so much blood tissue soft flabby cortex looks slightly swollen. Stomach. Veins in dependent parts full. M. M. soft easily torn. Duodenum presents slight pigmentary changes in the M. M. Intestines nothing abnormal noticed in ileum nor in the jejunum. Peyer's patches are very indistinct.

Liver normal size. On section lobules indistinct. Larger vessels contain blood. Tissue looks healthy.

Brain nothing abnormal noticed in vessels or substance.